

Spine

Maximum Medical Improvement and Impairment Rating

TDI Division of Workers'
Compensation

Material Disclaimer

The material presented in this presentation is made available by the Texas Department of Insurance/Division of Workers' Compensation (TDI-DWC) for educational purposes only. The material is not intended to represent the sole approach, method, procedure or opinion appropriate for the medical situations discussed.

Video Disclaimer

The videos presented in this training are made available by the Texas Department of Insurance/Division of Workers' Compensation (TDI-DWC) for educational purposes only. The videos are not intended to represent the sole method or procedure appropriate for the medical situation discussed.



When there is conflict between...



The Division of Workers' Compensation (DWC)
Statutes/Rules/Appeals Panel Decisions (APDs)



and, the *AMA Guides*



Be aware of when DWC
Statutes/Rules/APDs take precedence



Maximum Medical Improvement (MMI)

§401.11(30)s

- Definition of MMI: *"The earliest date after which, based on reasonable medical probability, further material recovery from or lasting improvement to an injury can no longer reasonably be anticipated."*

Maximum Medical Improvement (MMI)

Rule §130.1(c)(3)

- Assignment of an impairment rating for the current compensable injury shall be based on the injured employee's condition on the MMI date considering the medical records and the certifying examination

Considerations to keep in mind

- Most Spine Impairments fall in DRE I – II, and some reach the threshold for III
- Be aware of structural inclusions and the functional criteria necessary to reach the threshold for the different criteria
- DRE IV-VIII are not common
 - Make sure you know how to determine the IR for these categories
 - Some differences in how this is done for the cervicothoracic / thoracolumbar vs lumbosacral

Impairment Rating

Spine DRE I - Complaints or Symptoms

- No significant clinical findings
- No muscle guarding or history of guarding
- No documented neurologic impairment
- No loss of structural integrity on F/E x-rays
- No indication of impairment related to injury or illness
- No structural inclusions
- 0% whole person impairment

Impairment Rating

Spine DRE II: Minor Impairment

Structural Inclusions

- Compression fracture < 25%
- Non-displaced posterior element fractures
- Transverse or spinous process fracture with displacement in L and C spine; T spine is unclear

Clinical Findings/Differentiators

- Significant intermittent or continuous muscle guarding or spasm or nonuniform loss of range of motion, dysmetria, is present or has been observed and documented by a physician
- Non-verifiable radicular complaints
- No objective signs of radiculopathy
 - loss of relevant reflex(es)
 - 2 cm or greater atrophy with circumferential measurements of relevant extremity
- No loss of structural (motion segment) integrity lateral view flexion/extension x-rays
- 5% whole person impairment



Guarding differentiator, Table 71, page 109

- "Paravertebral muscle guarding or spasm or non-uniform loss of motion, dysmetria"
- Not further defined in the Guides, 4th Ed.
- When using "spasm" or "non-uniform range of motion" or other differentiators – don't just list them; explain which were used and why in your report.



Some thoughts on non-uniform loss of ROM, dysmetria

- Non-uniform loss of ROM
 - Does this mean asymmetry?
 - One plane of motion? More than one plane?
- Dysmetria
 - Lack of coordinated movement
 - How does this apply to spine?



Some thoughts on muscle guarding and spasm

- **Muscle Guarding** is a **voluntary** contraction of a muscle to minimize motion or agitation of the injured or diseased tissue.
 - It is not true muscle spasm because the contraction can be relaxed.
 - In the spine, it may be associated with reproducible loss of motion, which may be non-uniform loss.
- **Muscle Spasm** is a sudden **involuntary** contraction of a muscle or a group of muscles, usually associated with recent injury.
 - To differentiate true muscle spasm from voluntary muscle contraction, the individual should not be able to relax the contractions.
 - The spasm should be present standing as well as in the supine position.



Some thoughts on muscle guarding and spasm

- "SPASM" can be over-utilized and misused, especially in electronic health records (EHRs)
- Spasm is not typically seen at MMI
- Has low inter-rater reliability, sensitivity, specificity and poor validity



DRE I: Complaints or Symptoms

VS.

DRE II: Minor Impairment

There are the DRE differentiators to consider,
and

Rule 130.1(c)(3) "Assignment of an impairment rating for the current compensable injury shall be based on the injured employee's condition on the MMI date...."



DRE I vs. DRE II

What if there is a documented history of differentiators that are not present at MMI?

DRE I

Criteria requires “...no muscle guarding or history of guarding...”

- DRE I for the IE’s lack of muscle guarding or loss of range of motion at the time of MMI would comply with Rule 130.1(c)(3)
- But the IE’s history of muscle spasms and loss of ROM documented in the records as having occurred prior to MMI would potentially not meet DRE I criteria

DRE Lumbosacral Category I: Complaints or Symptoms

Description and Verification: The patient has no significant clinical findings, no muscle guarding or history of guarding, no documentable neurologic impairment, no significant loss of structural integrity on lateral flexion and extension roentgenograms, and no indication of impairment related to injury or illness.

Structural Inclusions: None.

Impairment: 0% whole-person impairment.

DRE I vs. DRE II

What if there is a documented history of differentiators that are not present at MMI?

DRE II

Criteria states, "...may include significant intermittent or continuous muscle guarding that has been observed and documented by a physician, nonuniform loss of range of motion..."

- The IE's documented history of muscle spasm and loss of range of motion prior to MMI would meet DRE II criteria
- The IE's lack of muscle spasm and loss of range of motion at the time of MMI, would potentially not comply with Rule 130.1(c)(3)

DRE Lumbosacral Category II: Minor Impairment

Description and Verification: The clinical history and examination findings are compatible with a specific injury or illness. The findings may include significant intermittent or continuous muscle guarding that has been observed and documented by a physician, nonuniform loss of range of motion (dysmetria, differentiator 1, Table 71, p. 109), or nonverifiable radicular complaints. There is *no* objective sign of radiculopathy and *no* loss of structural integrity. See Table 71, differentiator 1 (p. 109).

Structural Inclusions: (1) Less than 25% compression of one vertebral body; (2) posterior element fracture *without* dislocation (not developmental spondylolysis); the fracture is healed, and there is no loss of motion segment integrity.

A spinous or transverse process fracture with displacement without a vertebral body fracture is a category II impairment because it does not disrupt the spinal canal.

Impairment: 5% whole-person impairment.

DRE I vs. DRE II

What if there is a documented history of differentiators that are not present at MMI?

Also consider, the Guides Differentiators in Table 71, page 109 include:

1. Guarding = "Paravertebral muscle guarding or spasm or nonuniform loss of range of motion, dysmetria, is present or has been documented by a physician" per Table 71, p. 109

DRE I vs. DRE II

Table 71, 1. Guarding

APD 080966-s –...“by placing the word ‘or’ between guarding, spasm and nonuniform loss of ROM we read those terms in the disjunctive. We read the Guarding portion of Table 71 to say **guarding can be used as a differentiator if guarding or spasm or nonuniform loss of ROM is present or has been documented by a physician**, not that all three items of guarding, spasm and nonuniform loss of ROM must be present or documented by a physician before it can be used as a differentiator.”

DRE 1 vs. DRE II

Considering rule 130.1(c)(3); DRE I, DRE II; and APD 080933-s

- This is an area where there is variability in interpretation
- There may be a difference of medical opinion
- You must determine the appropriate DRE category and *sufficiently explain* this in your report, based on the compensable injury and case specific facts

DRE I vs. DRE II

Simply listing the differentiators from the Guides is insufficient

- Document which specific DRE differentiator(s) are present at MMI.
- Describe where the differentiator(s) are found:
 - in the records
 - on your exam



DRE I vs. DRE II

CONCLUSION:

- **The key is to sufficiently explain your rationale for your choice of DRE I or DRE II** so that others reading your report, including an administrative law judge, clearly understand your IR and rationale.
- Failure to sufficiently explain your rationale can lead to receipt of an LOC, or your report being overturned.



Impairment Rating

Spine DRE III: Radiculopathy

- Radiculopathy may be accepted or a compensable condition, with corresponding clinical findings, BUT must reach threshold of “significant signs” to be ratable as DRE III
- “Significant signs” of radiculopathy
 - Loss of relevant reflex(es)
 - includes decreased and absent relevant reflex(es)
 - 2 cm or greater atrophy (at same location) with circumferential measurements of relevant extremity



Impairment Rating

Spine DRE III: Radiculopathy

- APDs 040924, 091039, 111710 - **Loss of relevant reflex(es) includes *decreased* and *absent* reflexes.**
- APD 030091-s Radiculopathy requires > 2 cm of atrophy and/or loss of relevant reflex(es).
- APD 072220-s clarified that DRE III radiculopathy was for atrophy of **2 cm or more.**



Case 1

History of Injury

- 28-year-old warehouse worker lifted 50 pound box at work 4 months ago
- Experienced lower back pain and right lower extremity pain



Case 1

Treatment History - Date of Injury

- Occupational medicine physician diagnosed lumbar sprain
- Initial treatment naproxen, cyclobenzaprine and tramadol
- Released to return to work with restrictions not to lift more than 20 pounds
 - employer able to accommodate restrictions



Case 1

Treatment History - 3 Weeks Post Injury

- 6 PT visits in occupational medicine clinic consisting of hot packs, electrical stimulation, and some exercises involving lumbar and hip flexion stretching
- Follow up at three weeks post injury the IE reported worsening symptoms over the past two weeks with progression of pain extending into right buttock with “numbness and tingling” sensation in right lateral thigh and leg to the front of the shin.

Case 1

Treatment History - 3 Weeks Post Injury

- NSAID switched to meloxicam and told to discontinue physical therapy
- Continued to work with restrictions



Case 1

Treatment History - 4 Weeks Post Injury

- Lumbar spine plain film x-rays obtained
- Show moderate spondylosis at L4/L5



Case 1

Treatment History - 6 Weeks Post Injury

- Occupational medicine physician referral to PMR physician
- Low back and right lower extremity symptoms increased with sitting, bending forward, lifting and in morning; better with standing and walking
- Left lumbar list



Case 1

Treatment History - 6 Weeks Post Injury

- PMR records reported
 - VAS 8/10 and Oswestry score 54%
 - Symptom diagram demonstrated right > left lumbosacral pain extending into right buttock, right lateral thigh, leg and dorsum of foot



Case 1

Treatment History - 6 Weeks Post Injury

- Lumbar flexion fingertips to knees with increased low back, right buttock and posterior thigh pain, extension slightly decreased with increased right low back pain
- Patellar and Achilles DTRs 2+ bilaterally
- Medial hamstring DTR not tested



Case 1

Treatment History - 6 Weeks Post Injury

- Decreased sensation right lateral thigh, leg and dorsum of foot
- Right ankle dorsiflexion, EHL and hip abduction 4+/5
- **Diagnosis**
 - Right L5 radiculopathy secondary to suspected L4/L5 HNP

Case 1

Treatment History - 6 Weeks Post Injury

- PMR ordered a non-contrast lumbar MRI scan



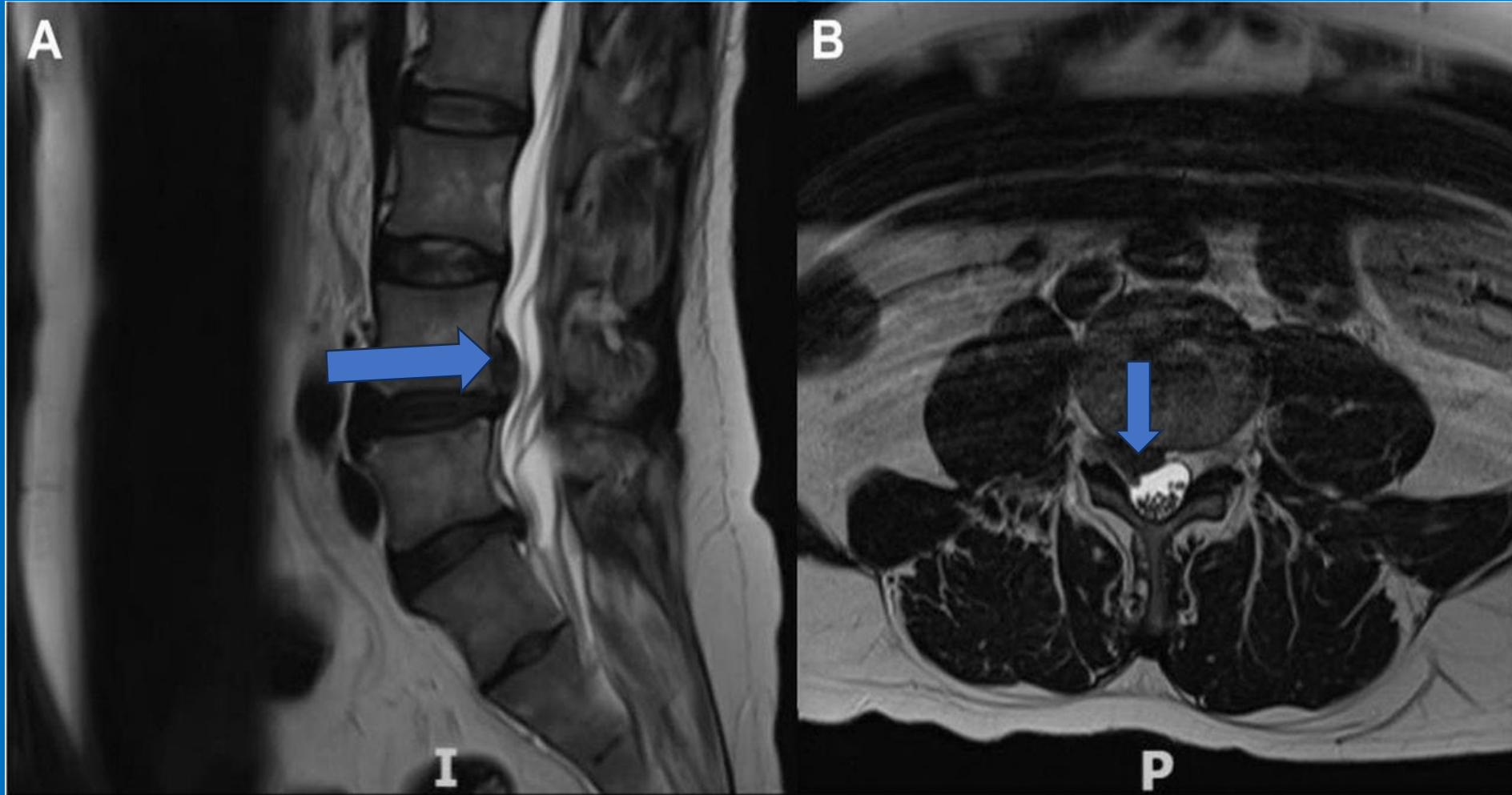
Case 1

Treatment History - 8 Weeks Post Injury

Lumbar MRI scan report

- Extruded right paramedian disc herniation, with cranial migration of disc content, causing an impression on the ventral surface of the dural sac and obliteration of the right lateral recess of the vertebral canal, with compression of the descending right L5 nerve root
- Disc desiccation at L4/L5 and L5/S1
- No other findings noted at other disc levels

Case 1





Case 1

Treatment History - 10 Weeks Post Injury

- Transforaminal Epidural Steroid Injection (ESI) at 10 weeks post injury
- Significant relief right lower extremity symptoms for 3 weeks
- Right lower extremity symptoms recurred with sitting and bending forward
- Working restricted duty
- Preauthorization denial for repeat ESI

Case 1

Designated Doctor (DD) Evaluation - 16 Weeks Post Injury

- You are asked to evaluate the injured employee for MMI / IR. You evaluate him at ~ 4 months after the DOI. You document:
 - The mechanism of injury (MOI)
 - Timeline of subjective symptoms and objective findings
 - Imaging findings
 - Response to treatment



Case 1

DD Evaluation - 16 Weeks Post Injury

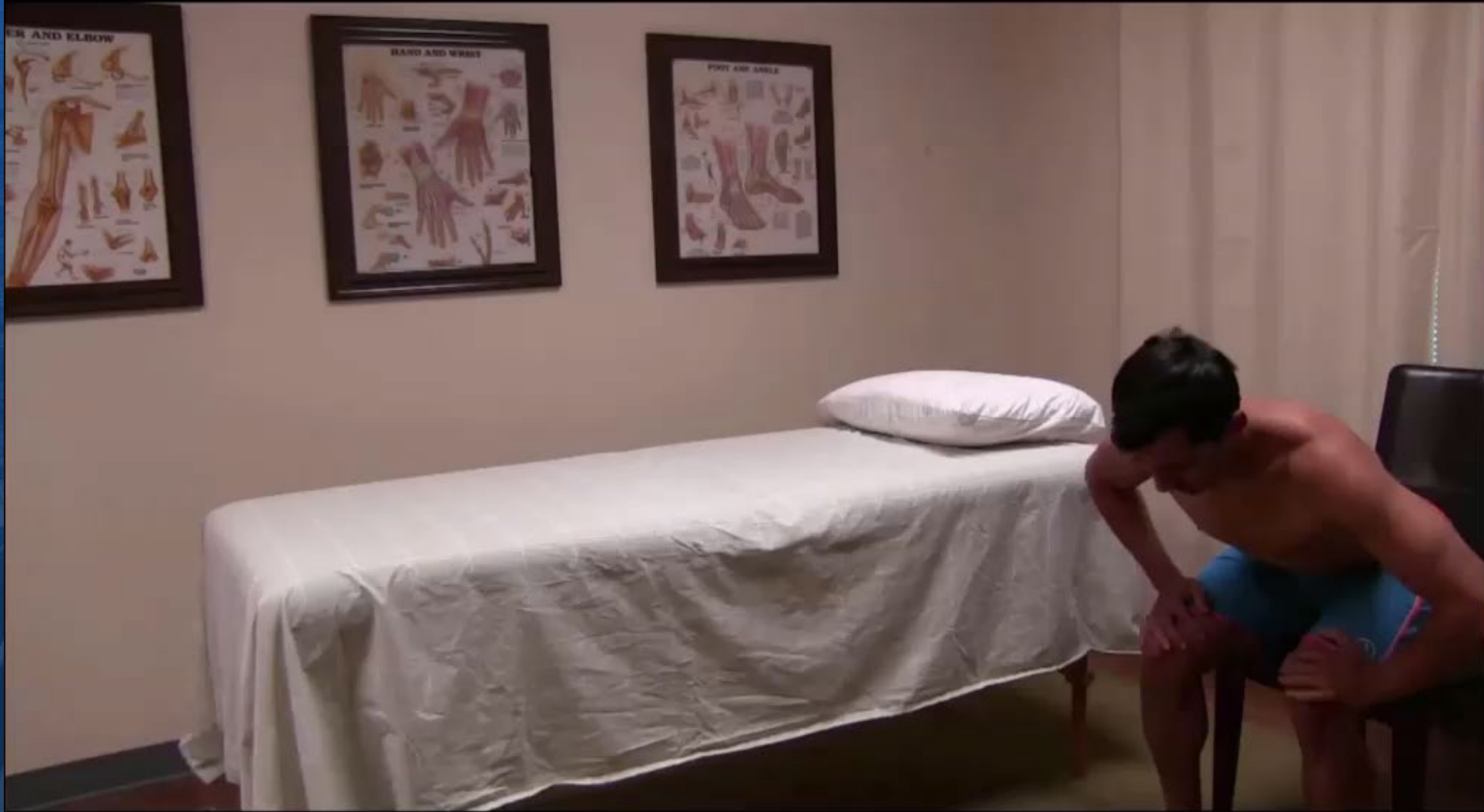- Warehouse worker for 5 years, present employer for past 2 years
- Currently working with restrictions
- No co-morbid medical conditions or relevant past medical history
- Sleep disturbed due to back and leg pain

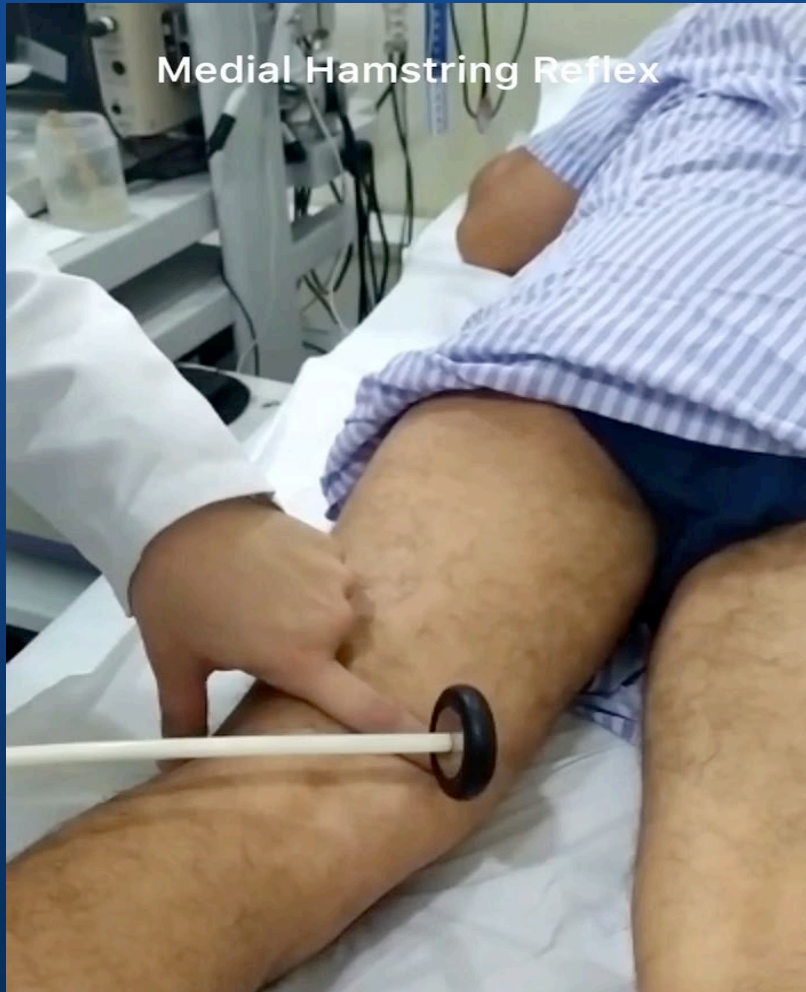

Case 1

DD Evaluation - 16 Weeks Post Injury

- No history of psychological distress or treatment
- Oswestry score 52%
- Pain scale 7/10
- Symptom diagram shows right low back, buttock, posterior thigh and lateral leg pain extending to dorsum of right foot
- Preauthorization denial appealed





Medial Hamstring DTR Prone

de Carvalho Neto EG, Gomes MF, Damiani Monteiro M, *et al* The medial hamstring (L5) reflex. *Practical Neurology* 2020;**20**:472-473



Example Medial Hamstring DTR Supine

Esene IN, Meher A, Elzoghby MA, El-Bahy K, Kotb A, El-Hakim A. Diagnostic performance of the medial hamstring reflex in L5 radiculopathy. *Surg Neurol Int.* 2012;3:104. doi: 10.4103/2152-7806.100862. Epub 2012 Sep 13



Medial Hamstring Reflex

Summary

- The MHR is very important in rating L5 radiculopathy
- The L5 innervated muscles are unlikely to show 2 cm or less of measurable girth atrophy – we will discuss this more in a few minutes
- Increase your proficiency by routinely evaluating the MHR prone and supine
- Routinely list your findings for the MHR in your report

Case 1

DD Physical Exam – 16 Weeks Post Injury

- Vitals
 - height 70 inches
 - weight 175 lbs.
 - BP 130/82
 - pulse 65
 - respiration 16
- Able to rise from sitting to standing with difficulty assuming lumbar lordosis
- Ambulates with normal gait

Case 1

DD Physical Exam (cont'd) – 16 Weeks Post Injury

- No scars on back or trunk
- Slight left trunk list
- Able to walk on heels and toes, squat and perform 10 calf raises on each leg without obvious weakness
- 4/5 strength right EHL, right tibialis anterior, and right hip abductors; otherwise manual muscle testing shows 5/5 strength

Case 1

DD Physical Exam (cont'd) – 16 Weeks Post Injury

- Patellar and Achilles DTRs 2+ bilaterally
- Medial hamstring DTRs tested supine absent bilaterally; **prone absent on right, 1+ on left**
- Sensation slightly decreased over right posterior thigh and anterolateral leg and dorsum of foot
- Symmetric thigh and calf circumference

Case 1

DD Physical Exam (cont'd) – 16 Weeks Post Injury

- Right supine SLR to 45° with increased sharp lower back pain extending into right buttock and posterior thigh
- Worsened with ankle dorsiflexion and hip adduction/internal rotation
- Left supine SLR 70° with only hamstring tightness/discomfort



Case 1

DD Physical Exam (cont'd) – 16 Weeks Post Injury

- Negative femoral nerve root tension signs
- Tenderness with palpation and hypertonicity of right lower lumbar paraspinal muscles at L4/L5/S1

Case 1

Based on medical records and physical exam, what is compensable injury for certifying MMI and IR?

130.1(c)(3)



Case 1

What is compensable injury for certifying MMI and IR?

- A. Lumbar sprain
- B. Right L5 radiculopathy
- C. Lumbar sprain and right L5 radiculopathy secondary to L4/L5 HNP
- D. Lumbar sprain, right L5 radiculopathy secondary to L4/L5 HNP and L4/L5 disc desiccation



Case 1

**Has MMI been
reached?
If so, on what date?**

*(May not be greater than statutory MMI
date shown on DWC Form-032)*



Case 1

**Has MMI been reached?
If so, on what date?**

- A. Yes, date of initial PMR visit, 6 weeks post injury
- B. Yes, date of TF ESI, 10 weeks post injury
- C. Yes, date of DD exam, 16 weeks post injury
- D. No, not at MMI



Case 1

What does the ODG say about these treatments?

Repeat Transforaminal ESI?

Different approach to PT?

- Directional based exercises?
- McKenzie? Other?

Discectomy?

Other?





Case 1

**Any Questions
about Case 1?**



Case 1- The Sequel

DD Evaluation – 52 Weeks Post Injury

- Underwent L4-5 discectomy 18 weeks after injury
- Discharged from PT with independent home and gym exercise program 32 weeks post injury
- Illegible handwritten PT discharge notes



Case 1- The Sequel

DD Evaluation – 52 Weeks Post Injury

- Medical records document **PMR follow-up 40 weeks post injury**
 - Reports significant improvement with discectomy and PT, but persistent low back and right lower extremity pain with sitting, bending and lifting, "2 - 3/10"
 - Working full duty, no lifting >50 lbs



Case 1- The Sequel

DD Evaluation (con't) - 52 Weeks Post Injury

- **PMR follow-up 40 weeks post injury** (cont'd)
 - No lumbar list
 - Decreased lumbar flexion with deviation to left and increased low back and right buttock pain, slightly decreased extension
 - Right SLR at 60° produces right low back and buttock pain, pain increased with ankle DF



Case 1- The Sequel

- DD Evaluation (con't) - 52 Weeks Post Injury
 - Medical records document **PMR follow-up 40 weeks post injury** (cont'd)
 - LE strength 5/5 bilaterally
 - LE DTRs bilaterally symmetric
 - Will continue home exercise program
 - Released to full duty, no restrictions
 - Follow-up as needed

Case 1- The Sequel

DD Evaluation - 52 Weeks Post Injury

DD's list of IE's Current Complaints

- Oswestry score 16%
- Pain scale 2-3/10; pain drawing shows right low back, right buttock and posterior thigh pain
- Indicates recurrent low back pain with repeated bending forward, sitting/driving greater than 45 minute intervals, lifting > 50 lbs.
- Reports some relief of low back and RLE symptoms with HEP and ibuprofen prn



Case 1- The Sequel

DD Evaluation - 52 Weeks Post Injury

DD Clinical Exam

- Vitals
 - height 70 inches
 - weight 175 lbs
 - BP 120/78
 - pulse 65
 - respiration 16
- Able to slowly assume lumbar lordosis from sitting to standing
- No list or deformity
- Ambulates with normal gait

Case 1- The Sequel

DD Evaluation - 52 Weeks Post Injury

DD Exam

- Lumbar flexion fingertips to proximal shin, with increased right low back and buttock pain, full extension with moderate low back pain
- Able to walk on heels and toes, squat and perform 10 calf raises on each leg without obvious weakness
- 5/5 strength right EHL; 5/5 right tibialis anterior; and 5/5 right hip abductors

Case 1- The Sequel

DD Evaluation - 52 Weeks Post Injury

- DD Exam
 - Left lower extremity strength 5/5 all levels
 - Patellar and Achilles DTRs 2+ bilaterally
 - Medial hamstring DTRs 1+ bilaterally supine and prone
 - Sensation is intact and bilaterally symmetrical

Case 1- The Sequel

DD Evaluation - 52 Weeks Post Injury

- DD Exam
 - Symmetric thigh and calf circumference
 - Right supine SLR to 62° with increased lower back pain extending into right buttock and posterior thigh
 - Worsened with ankle dorsiflexion and hip adduction/internal rotation

Case 1- The Sequel

DD Evaluation - 52 Weeks Post Injury

- DD Exam
 - Left supine SLR 75° with hamstring tightness/discomfort only
 - Tenderness with palpation of right lower lumbar paraspinal muscles at L4/L5/S1
 - No spasm or guarding present

Case 1 – The Sequel

**Has MMI been reached?
If so, on what date?**

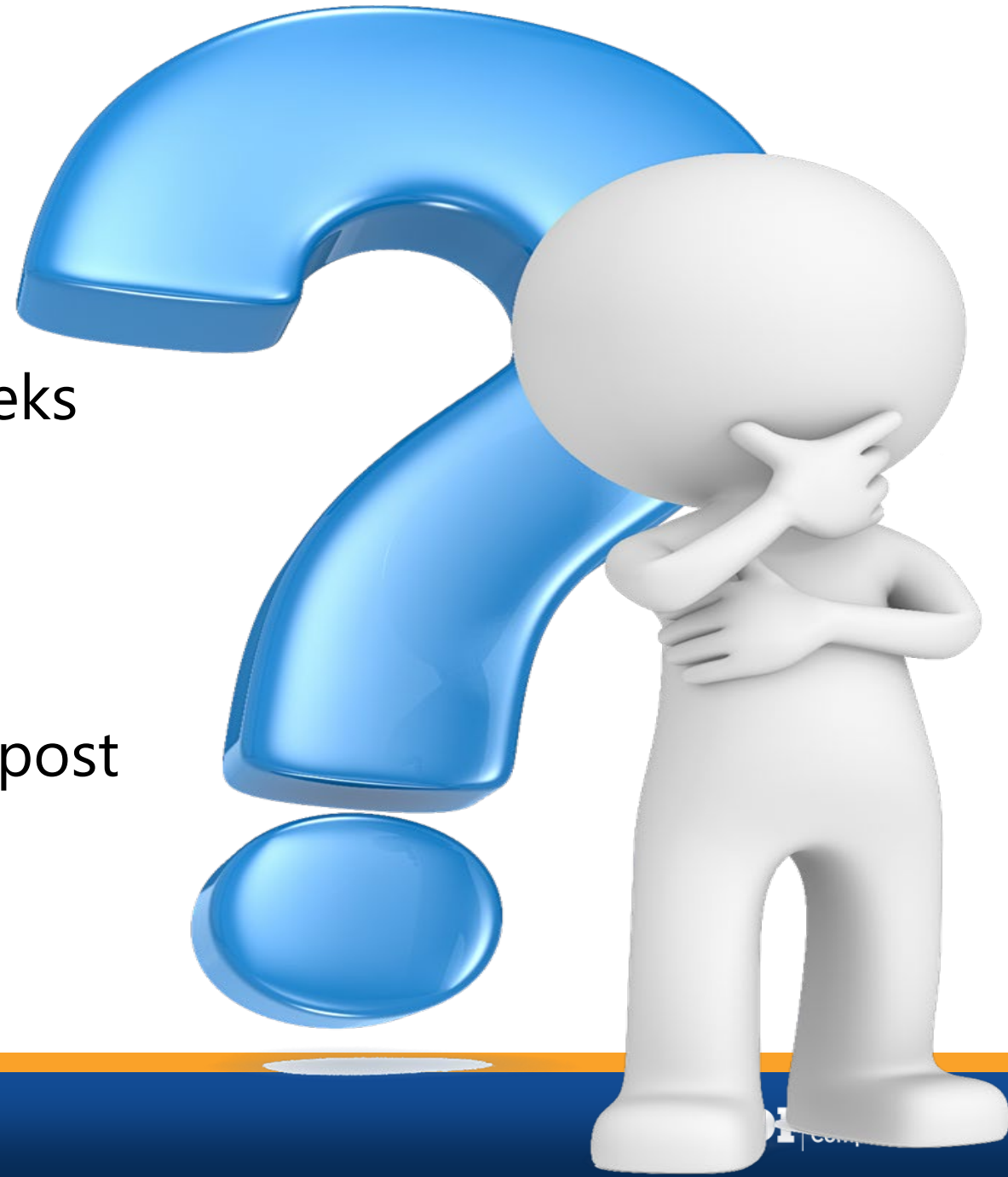*(May not be greater than statutory MMI
date shown on DWC Form-032)*



Case 1 – Spine MMI/IR

**Has MMI been reached?
If so, on what date?**

- A. Yes, date of PT discharge, 32 weeks post injury
- B. Yes, date of PMR follow-up, 40 weeks post injury
- C. Yes, date of DD exam, 52 weeks post injury
- D. No, not at MMI



Case 1 – The Sequel

**On the MMI date,
what is the whole
person IR?**



Case 1 – The Sequel

On MMI date, what is whole person IR?

- A. DRE I = 0%
- B. DRE II = 5% for non-verifiable right L5 radiculopathy
- C. DRE III = 10% for right L5 radiculopathy



Case 1 the Sequel

Clinical radiculopathy vs. Ratable radiculopathy

AMA Guides vs.
DWC Rules/Appeals
Panel Decisions

See AMA Guides:

Dermatomal sensory
loss, Myotomal motor
loss, Electro-diagnostics,
Loss of reflex(es),
Atrophy

See APDs:

Loss of relevant reflex(es)
2+ cm atrophy
030091-s, 142524,
040924, 091039, 111710,
072220-s, 051456, 080375



Case 1- The Sequel

- **What about L5 Reflex?**
 - Check prone and supine where you can observe the medial hamstring
 - Current EBM supports validity
- **S1 reflex?**
 - Absent bilaterally in a significant proportion of older population
- **C8? T1?**
 - These roots do not have corresponding reflexes



Case 1- The Sequel

- Can you use the ROM Model for an L5 or S1 radiculopathy or C8 or T1 radiculopathy if you can't obtain reflexes bilaterally?
 - Rarely used and requires significant explanation why DRE is not applicable or why more data is needed to place IE in correct DRE
 - Also, if used, use as a "differentiator", to assist you in sorting the appropriate DRE category



Case 1- The Sequel

ROM Model as a Differentiator

- Table 75, pg. 113 for the structural condition.
- Combine with the ROMS.
 - 3 consecutive measures of flexion alternating with extension AND right LF alternating with left LF. (in up to 6 repetitions) that meet CONSISTENCY criteria
 - Must use tightest of the SLR to look at SLR validity criteria - Table 81, pg. 126-128
- Combine with the sensory motor deficits as per Table 83 on page 130 and Table 11 and 12
- **You DO NOT use the absolute #, you use that # to justify using the higher category of DRE III. Be sure to explain.**
- **Best Practice:** recommend ROM model when there are other radicular findings such as weakness in a myotome or loss of sensation in a dermatomal pattern but does not meet the DRE III criteria of reflexes



Case 1 The Sequel

Any Questions?



Case 2

History of Injury

- 42 year-old male taxi driver involved in rear-end motor vehicle accident 10 months ago
- Evaluated by EMS at scene of accident
 - Neck pain and occipital headache
 - No loss of consciousness, normal neurologic exam
 - Recommended for transport, patient denied

Case 2

Treatment History

- Saw chiropractor 1 week post injury
 - Neck pain, occipital headache w/ "hotness" into to right forearm and hand
 - Decreased cervical extension, right rotation and right lateral flexion with right neck pain
 - Deviation of head/neck to left during decreased extension
 - Palpation reveals hypertonicity and joint hypomobility C2/3-C6/7 R>L



Case 2

Treatment History

- Saw chiropractor 1 week post injury
 - Cervical x-rays show no evidence of fracture or dislocation
 - C5/C6 disc space narrowing, with marginal osteophyte anterior aspect of superior andplate at C6

Case 2

Chiropractor's Records

- Diagnosis of acute cervical sprain/strain with radiculitis
- Manipulation and soft tissue techniques
- Progression of exercise program – self mobilization, stretching, scapular strengthening with therabands
- 14 visits over 12 weeks

Case 2

Chiropractor's Records (cont'd)

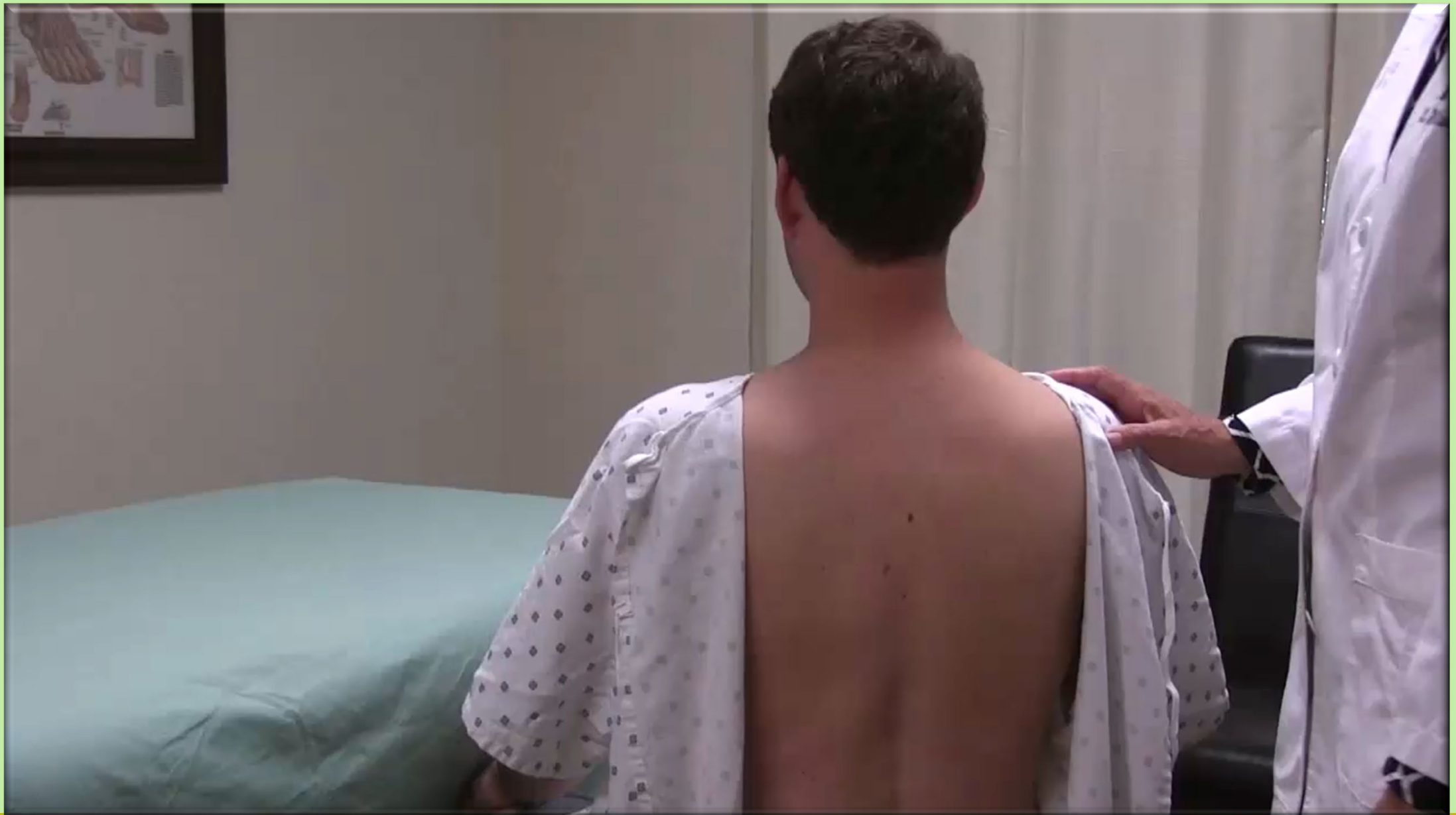12 Week Follow-Up

- Continued 8/10 pain scale
 - Reduced cervical ROM with pain
- Tenderness to palpation of C-spine and superior traps
- Bilateral +2 upper extremity DTRs
- Sensation decreased across C5-C7
- Motor strength noted as 4-/5 biceps, triceps, brachioradialis and deltoids
- Additional PT request denied

Case 2

DD Medical History - 24 Weeks Post Injury

- Chief complaint persistent 8/10 neck pain
- Working full duty without restrictions for last 14 weeks
 - He feels this is making him get worse, especially since additional PT has been denied
 - He feels he needs more PT to get better
- Neck Disability Index (NDI) score 52%
- Additional PT has been denied
- Referred to pain management for C-ESIs





Case 2

DD Physical Exam - 24 Weeks Post Injury

- Vitals
 - height 72 inches
 - weight 175 lbs
 - BP 118/78
 - pulse 64
 - respiration 14
- He is cooperative with history and exam but repeatedly discusses delays in care and “unreasonable” treatment by his employer and adjuster



Case 2

DD Physical Exam (cont'd) - 24 Weeks Post Injury

- No scars on the neck or visible deformity, scoliosis, or kyphosis
- Cervical ROM full, with c/o of increased pain
- No palpable muscle spasm of cervical paraspinal muscles
- Upper extremity DTRs +2 bilaterally
- Muscle strength is 5/5 all levels
- Sensation decreased C5-7 bilaterally

Case 2

Based on medical records and physical exam, what is compensable injury for certifying MMI and IR?

130.1(c)(3)



Case 2

What is compensable injury for certifying MMI and IR?

- A. Cervical sprain/strain status post rear-end MVA
- B. Suspected cervical HNP
- C. A & B
- D. Other



Case 2

**Has MMI be reached?
If so, on what date?**

*(May not be greater than statutory
MMI date shown on DWC Form-
032)*



Case 2

**Has MMI be reached?
If so, on what date?**

- A. Yes, 12 weeks post injury after 14 visits with DC
- B. Yes, 24 weeks post injury on date of DD exam
- C. Other date?
- D. No, not at MMI



Case 2

**On the MMI date,
what is the whole
person IR?**



Case 2

**On the MMI date,
what is the whole
person IR?**

- A. DRE I = 0%
- B. DRE II = 5%
- C. DRE III = 15%
- D. DRE IV = 25%



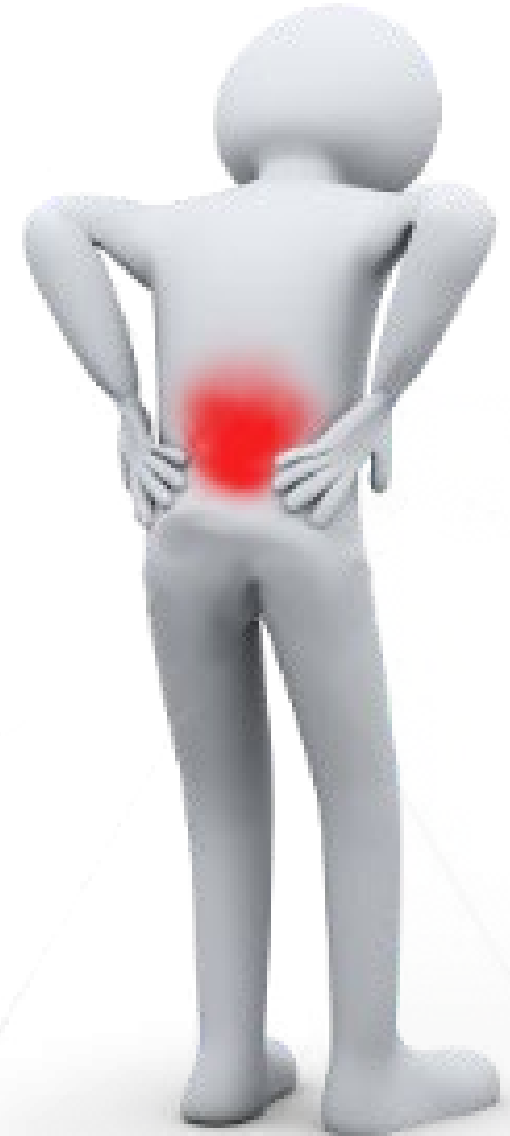Case 2

Any Questions?

Case 3

History of Injury

28-year-old male landscape worker began having acute low back and right buttock pain after lifting a tree 8 months ago





Case 3

Treatment History

- Initially seen day of injury at occupational medicine clinic
- Diagnosed with lumbar sprain/strain
- Treated with cyclobenzaprine and Ibuprofen
- 6 visits PT over 3 weeks at occupational medicine clinic
 - hip/lumbar flexion and rotation stretching, and some “stabilization” exercises



Case 3

Treatment History

- Released to return to work with restrictions
- Employer did not accommodate restricted duty and reportedly said “come back when you are 100%”
- **10 days** post injury reported pain and numbness in right posterior thigh and lateral calf



Case 3

Treatment History

- 14 days post injury, exam demonstrates weakness in the right hamstring, right calf and toe flexors and numbness of the lateral foot
- Had positive “crossed straight leg raise”, left straight leg raise reproduced pain in the right buttock and posterior thigh
- Left straight leg raise reproduced right calf pain



Case 3

Treatment History

- **4 weeks** post injury x-rays showed moderate spondylosis at L5/S1 with bilateral pars defects with a Grade I isthmic spondylolisthesis also at L5/S1
 - No evidence of segmental instability or alteration of motion segment stability on standing flexion and extension views



Case 3

Imaging

- **8 weeks** post injury, lumbar MRI scan obtained showing disc desiccation at L5/S1 and 7 mm right posterolateral L5/S1 HNP displacing right S1 nerve root
- Chronic bilateral pars defects well established without increased T2 or inversion recovery signal changes consistent with acute injury



Case 3

Treatment History

- **14 weeks** post injury, had translaminar lumbar epidural steroid injection at L5/S1 without significant or lasting improvement
- **20 weeks** weeks post injury, underwent right L5/S1 hemi-laminotomy/discectomy resulting in some relief of lower extremity symptoms



Case 3

Treatment History

- **24 weeks through 32 weeks** post injury – 14 visits of active PT. Initiated lumbar extension range of motion exercises progressing into strengthening exercises and work simulation
- **30 weeks** post injury - Repeat lumbar MRI scan with contrast showed post-operative changes and chronic bilateral pars defects without evidence of recurrent or residual disc herniation

Case 3

Treatment History

- **32 weeks** post injury – found another job supervising landscape crew; released to return to work full duty
- **36 weeks** post injury - treating doctor exam
 - Intermittent back and right lower extremity pain
 - Right SLR “positive” at 45 degrees
 - Moderately reduced lumbar flexion
 - Right Achilles DTR decreased



Case 3

Treatment History

- **36 weeks** post injury - treating doctor exam (cont'd)
 - Numbness to pinprick over the right lateral foot
 - Right ankle plantar flexion 4+/5
 - Did not want to pursue additional interventional pain management procedures
 - Continue with gabapentin, follow-up as needed

Case 3

DD Medical History - 52 Weeks Post Injury

- Chief complaint episodes of low back, right buttock and right posterior thigh pain after prolonged sitting, repeated bending forward or lifting
- Lower back, buttock and right lower extremity symptoms had improved significantly
- Continues to work as landscape crew supervisor
- Takes gabapentin, continues home exercise program





Case 3

DD Physical Exam - 52 Weeks Post Injury

- Vitals
 - height 70 inches
 - weight 175 lbs.
 - BP 124/78
 - pulse 62
 - respiration 13
- Pleasant affect, cooperative with history and exam, oriented to time, person, and place with normal attention span and concentration



Case 3

DD Physical Exam - 52 Weeks Post Injury (cont'd)

- Able to rise from sitting to standing with no abnormal motion
- Ambulates with normal gait
- Well healed approximate 3 cm surgical scar at midline lumbosacral junction
- No visible deformity, scoliosis or kyphosis

Case 3

DD Physical Exam - 52 Weeks Post Injury (cont'd)

- Able to walk on heels, weakness on right toe walk
- 4/5 strength of right toe flexion; ankle inversion and eversion; and knee flexion
- Lumbar flexion and right lateral flexion moderately decreased; extension and left lateral flexion essentially full

Case 3

DD Exam - 52 Weeks Post Injury

- Left SLR 65° limited by hamstring tightness
- Right straight leg raise limited to 45° where it produces right low back and right buttock pain, further increased with ankle dorsiflexion
- Patellar DTRs 2+ bilaterally; right Achilles DTR decreased

Case 3

DD Exam - 52 Weeks Post Injury (cont'd)

- Repetitive calf raises on right reveals some weakness
- 2 cm of right calf atrophy
- Some palpatory tenderness and hypertonicity of lumbar paraspinal muscles at right lumbosacral junction

Case 3

Based on medical records and physical exam, what is compensable injury for certifying MMI and IR?

130.1(c)(3)



Case 3

What is compensable injury for certifying MMI and IR?

- A. Lumbar sprain/strain
- B. Lumbar sprain/strain and persistent right S1 radiculopathy status post right L5/S1 hemilaminotomy/discectomy
- C. Other



Case 3

**Has MMI be reached?
If so, on what date?**

*(May not be greater than statutory
MMI date shown on DWC Form-032)*



Case 3

Has MMI be reached?

If so, on what date?

- A. Yes, 32 weeks post injury, date completed post-op PT and released to full duty work at new job
- B. Yes, 36 weeks post injury, date of treating doctor follow-up visit
- C. Yes, 52 weeks post injury, date of DD exam
- D. No, not at MMI



Case 3

**On the MMI date,
what is the whole
person IR?**



Case 3

On the MMI date, what is the whole person IR?

- A. DRE I = 0%
- B. DRE II = 5%
- C. DRE III = 10%
- D. DRE IV = 20%



Impairment Rating

Spine DRE III: Radiculopathy

Structural Inclusions

- Compression Fracture of 25% to 50%
- Displaced posterior element fractures that disrupt the spinal canal
- Not a spinous or transverse process fracture

Clinical Findings

- Loss of relevant reflex(es),
- 2 cm or greater atrophy with circumferential measurements of relevant extremity

Lumbosacral = 10% WP

Cervicothoracic & Thoracolumbar = 15% WP



Impairment Rating

Spine DRE III - Radiculopathy

Electrodiagnostic studies?

- APD 051456
 - EDX studies may be used to verify radiculopathy as stated page 102, DRE III and in Table 71, page 109, but are **insufficient alone** to rate as DRE III

Case 3

Any Questions?

Case 4

History of Injury

35-year-old male roofer fell from a roof sustaining T11 compression fracture and injury to the lumbar spine at work 12 months ago

Case 4

Treatment History

- Initially seen at ER
- X-rays demonstrating stable anterior compression fracture at T11 and minor spondylosis at L4-5 and L5-S1
- c/o LBP with left lower leg pain / numbness to the lateral calf
- Orthopedic surgeon initiated conservative treatment with bracing, pain medication and ADL/work modifications

Case 4

Treatment History

- 8 visits of PT over 10 weeks with significant improvement in symptoms and activity tolerance
- An MRI was ordered at follow up at 12 weeks, due to persistent tingling in the left lateral calf and dorsum of the foot

Case 4

Treatment History

- Lumbar MRI completed at 14 weeks demonstrated:
- Disc desiccation at L2-3 to L5-S1
- Disc bulges at L4-5 and L5-S1
- Far field findings on T2 and STIR images demonstrates edema in the T11 vertebral body and the T10 inferior and 12 superior endplates, but not elsewhere in the lumbar spine

Case 4

Treatment History

- At 6 months follow up, x-rays showed well healed T11 compression fracture with 20% loss of anterior vertebral body height
- Ortho follow up at 6 months
 - Essentially full ROM
 - Decreased sensation on the lateral calf and foot
 - No atrophy and MMT was 5/5 bilateral LEs
 - “much better after PT, doing well, has RTW, return as needed”

Case 4

DD Medical History - 9 months post injury

- Chief complaint low back pain
- Intermittent tingling on the top of the left foot
- Oswestry score 30%
- Pain scale 3/10

Case 4

- DD Exam – 9 Months Post Injury
 - Vitals
 - height 70 inches
 - weight 175 lbs
 - BP 128/78
 - pulse 68
 - respiration 14
 - Pleasant but somewhat flat affect, cooperative with history and exam,
 - Oriented to time, person, and place with normal attention span and concentration



Case 4

DD Exam – 9 Months Post Injury (cont'd)

- Able to rise from sitting to standing with no abnormal motion
- Ambulates with normal gait
- No visible deformity, scoliosis or kyphosis
- Able to walk on heels, toes and squat without weakness
- Lumbar flexion and extension and right/left lateral flexion all slightly decreased

Case 4

DD Exam – 9 Months Post Injury (cont'd)

- Diffuse thoracolumbar paraspinal muscle tenderness but no spasm
- No specific segmental areas of pain other than T10, T11 and T12
- SLR bilaterally 45° limited by hamstring tightness; produced low back pain on right and back pain into posterior thigh on the left



Case 4

DD Exam – 9 Months Post Injury (cont'd)

- Significant trigger point in the left posterior gluteus medius resulted in radiating pain in the left lateral pelvis and leg, to just past the knee
- Decreased sensation lateral calf and dorsum of the left foot
- 5/5 strength of bilateral lower extremities
- Patellar and Achilles DTRs 2+ bilaterally.
- No measurable atrophy of the left calf / thigh compared to the right

Case 4

Based on medical records and physical exam, what is compensable injury for certifying MMI and IR?

130.1(c)(3)



Case 4

What is compensable injury for certifying MMI and IR?

- A. T11 compression fracture
- B. Lumbar sprain / strain
- C. Disc desiccation L2-3 to L5-S1
- D. Disc bulges at L4-5 and L5-S1
- E. A and B
- F. All the above



Case 4

Compensable injury:

- A. T11 compression fracture, and**
- B. Lumbar sprain / strain are correct. Why?**
- C. **No**, to Disc desiccation L2-3 to L5-S1. **Why not?**
- D. No, to Disc bulges at L4-5 and L5-S1. Why not?



Case 4

**Has MMI been reached?
If so, on what date?**

(May not be greater than
statutory MMI date shown on
DWC Form-032)



Case 4

Has MMI been reached?

- A. Yes, 6 months post injury, date of the ortho follow-up and x-rays showing healed fracture
- B. Yes, date of designated doctor exam
- C. No, not at MMI



Case 4

On MMI date, what is whole person IR?



Case 4

On MMI date, what is whole person IR?

A. TS DRE II 5% c/w

LS DRE I 0% = **5%**

B. TS DRE II 5% c/w

LS DRE II 5% = **10%**

C. TS DRE II 5% c/w

LS DRE III 10% = **15%**



Case 4

On MMI date, what is whole person IR?

**A. TS DRE II 5% c/w
LS DRE I 0% = 5%**



Impairment Rating

Spine DRE II: Minor Impairment

Structural Inclusions

- Compression fracture < 25%
- Non-displaced posterior element fractures
- Transverse or spinous process fracture with displacement

Clinical Findings

- Muscle guarding
- Non-uniform loss of motion
- Dysmetria
- Non-verifiable radicular complaints
- No objective signs of radiculopathy
 - loss of relevant reflex(es)
 - 2 cm or greater atrophy with circumferential measurements of relevant extremity
- No loss of structural (motion segment) integrity lateral view flexion/extension x-rays
- 5% whole person impairment



What About Multilevel Compression Fractures?

WITHIN ONE of the 3 spinal regions

- **One** vertebral body compression fracture may be rated as DRE II, III or IV, depending on the percentage of compression – see pages 102-106
- “If the patient demonstrates the structural inclusions of two categories, the physician should place the patient in the category of the higher impairment percent” page 99

What About Multilevel Compression Fractures?

If there is a compression fracture in one spinal region, and a 2nd in another region...

...rate each region and then combine.

- Example:
 - 20 % **L1** Comp Fracture = DRE II = 5 % WP
 - 30 % **T12** Comp Fracture = DRE III = 15 % WP
 - No neurologic injury
 - Not able to be treated surgically
 - 15 % c/w 5 % = 19 % WP



What About Multilevel Compression Fractures?

DRE IV

- Multilevel spine (motion) segment structural compromise, such as fractures or dislocations may be rated as DRE IV (i.e., if there are several contiguous levels with compression fractures, there is often associated posterior ligament injury, which will result in segmental instability)
- ROM Model as a differentiator?

What About Multilevel Compression Fractures?

CONCLUSION:

- The AMA Guides are unclear
- At the discretion of examining doctor
- Provide rationale explaining why selected and how used methodology to assign IR
- **Show your work – Explain your answer**
- *“...plausible and relate to the impairment being evaluated...”*

Case 4

Any Questions?

Impairment Rating Spine DRE Categories IV - VIII

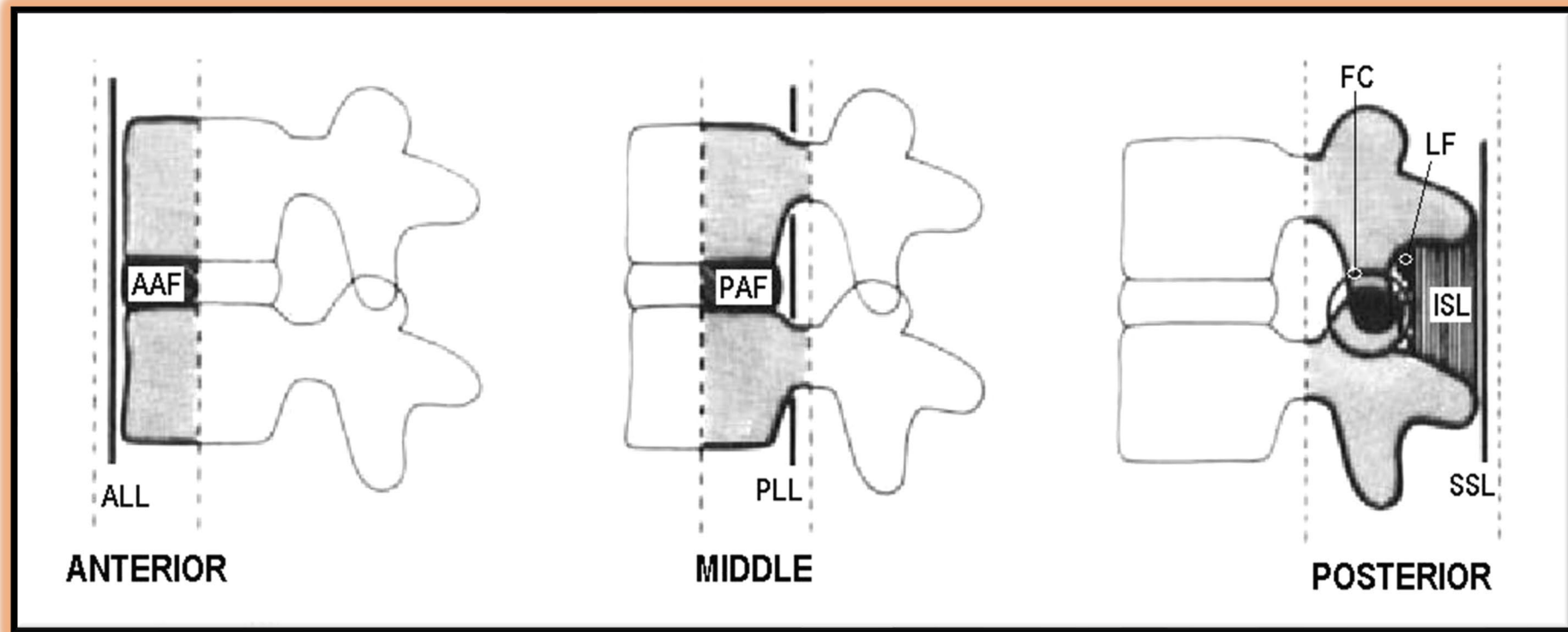
Conclusion

- Rare circumstances
- Refer to AMA Guides, pages 102-111

Spine DRE Categories IV – VIII

Schematic Spinal Anatomy

3 Column Theory (Denis)



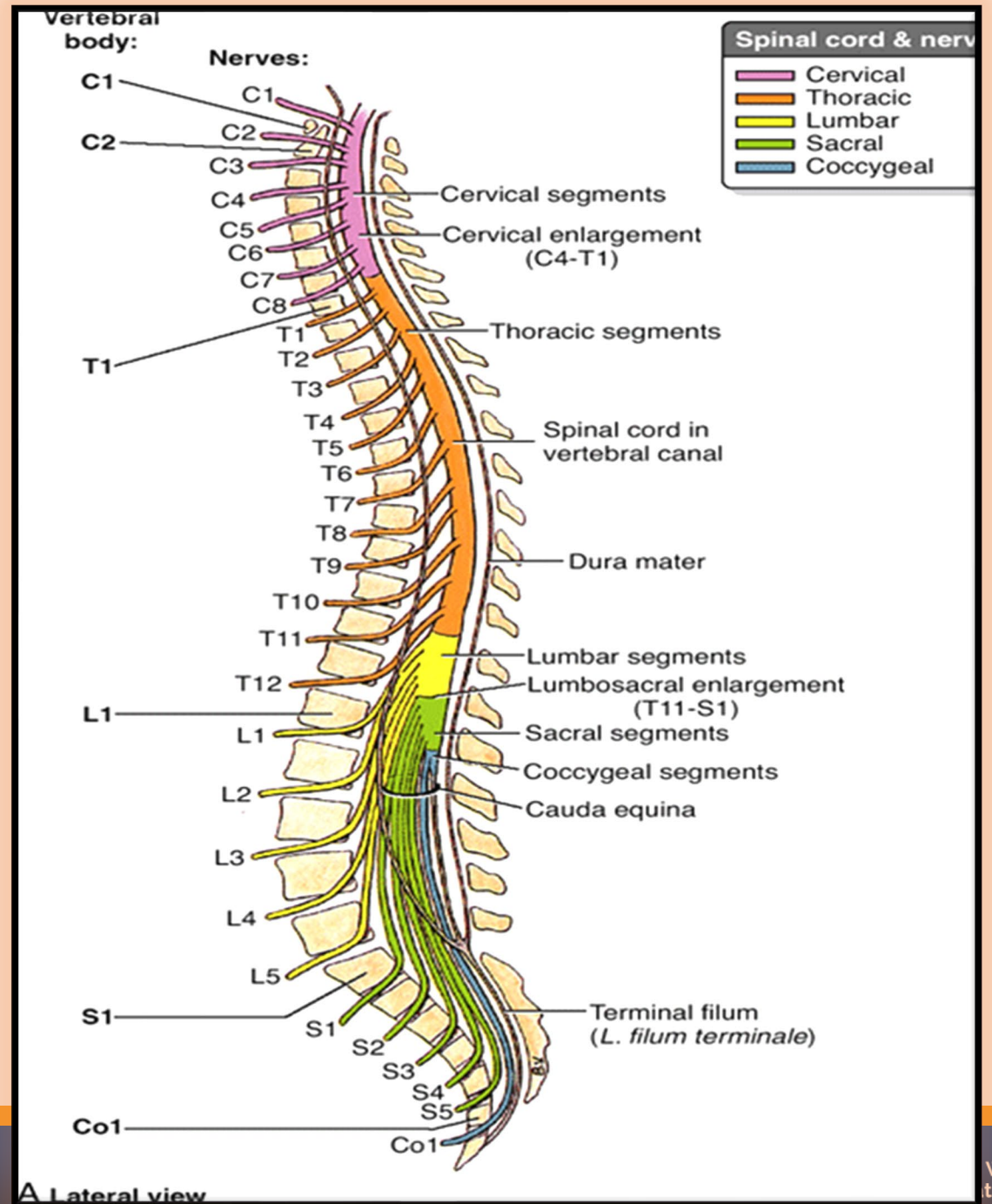
(ALL: Anterior longitudinal ligament, AAF: Anterior annulus fibrosus, PLL: Posterior longitudinal ligament, PAF: Posterior annulus fibrosus, SSL: Supraspinous ligament, ISL: Interspinous ligament, LF: Ligamentum flavum, FC: Facet capsule)

Spine DRE Categories IV – VIII

SPINAL CORD / CAUDA EQUINA / NERVE ROOT SCHEMATIC

Be aware of the spinal segmental levels where the different nerve roots emerge from the cord

- C8 between C7 and T1
- T12 above the conus medullaris (CM) starts to emerge at ~ T9
- L5 root start to emerge from the lumbosacral enlargement of the CM at ~ T11 and exits the spine between L5 and S1
- Sacral roots start to emerge from the lumbosacral enlargement of the CM at ~ T12 and L1





Spine DRE IV

Loss of Motion Segment Integrity or Multilevel Neurologic Compromise

Lumbar

- ≥ 5mm translation of one vertebra on another
(Guides state both ≥ 5mm and > 5mm)
- > 15° more angular motion at L5-S1 than L4-L5
- >11° more angular motion than adjacent levels

Cervical

- ≥ 3.5 mm translation of one vertebra on another
- > 11° more angular motion than adjacent levels

Lumbar and Cervical

Structural inclusions

- Compression Fracture >50%
- Multilevel spine segment structural compromise (fractures and dislocations)

Impairment Ratings

Lumbosacral = 20%

Thoracolumbar – 20%

Cervicothoracic = 25%

Impairment Rating

Spine Loss of Motion Segment Integrity

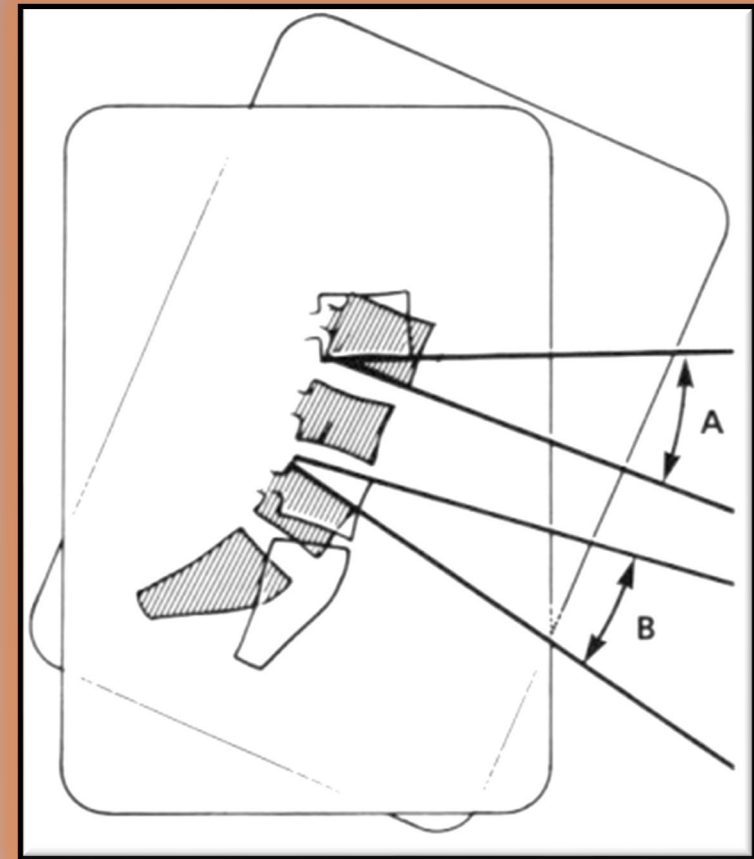
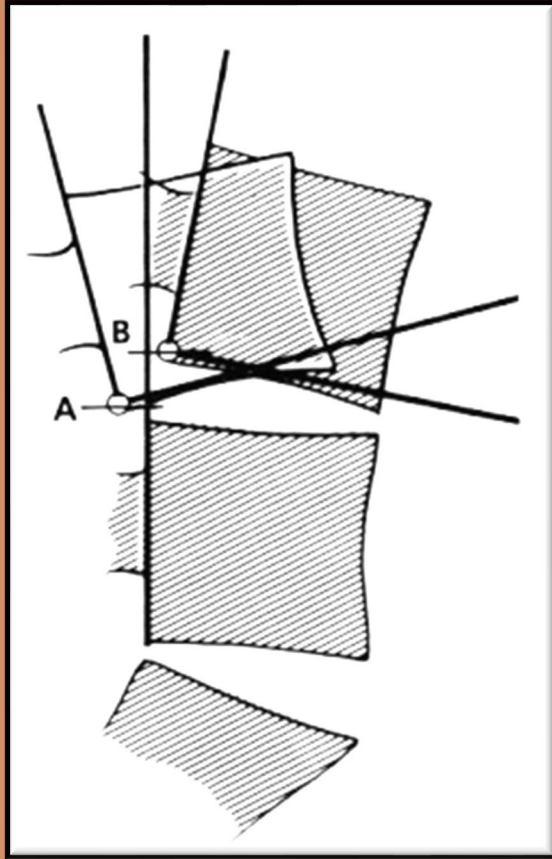


Figure 62
Loss of Motion Segment Integrity: Translation

Figure 63
Loss of Motion Segment Integrity: Angular Motion

Lumbosacral - DRE Category V

Radiculopathy AND Loss of Motion Segment Integrity (LOMSI)

- Must meet threshold for both
 - DRE Category III
 - structural OR radiculopathy criteria
 - DRE Category IV
 - documented loss of structural integrity
- 25% WP impairment



Lumbosacral - DRE Category VI

“Cauda Equina Like” Syndrome Without Bowel or Bladder Signs

- **Permanent** partial loss of bilateral lower extremity function
- No bowel or bladder symptoms
- Structural inclusions
 - None
- 40% impairment



Lumbosacral - DRE Category VII

“Cauda Equina Like” Syndrome With Bowel or Bladder Signs

- Bowel or bladder symptoms requiring use of assistive devices
- Evidence from EMG or cystometrogram may be present
- Structural Inclusions
 - None
- 60% impairment



Lumbosacral - DRE Category VIII Paraplegia

- Total or near total loss of lower extremity function
- Not just preference for use of wheelchair; must be structural damage to spine that causes anatomic damage to cauda equina
- Structural Inclusions
 - None
- 75% impairment



Lumbosacral DRE II - VIII

- Refer to summary Tables:
- 75– page 111 Lumbosacral
- LS spine DRE II – VIII are stand alone IR.
- DO NOT COMBINE WITH OTHER DRE.



Loss of Motion Segment Integrity (LOMSI) - Post operative Example

IE sustained a compensable low back injury

- Initial radiographs show 6mm translation between L4-5 on flexion/extension x-rays and MRI c/w injury at L4-5
- Underwent L4-5 fusion for bilateral L4 radic
- Completed appropriate postop PT

At MMI, flexion extension radiographs show solid fusion with no translation between L4-5

- Reflexes intact, no atrophy in thigh or calf
- Decreased sensation in the L4 dermatome on the right
- Appropriate DRE Category? DRE II = 5 %



Loss of Motion Segment Integrity (LOMSI) - Post operative Example

ALTERNATE SCENARIOS

What is the appropriate DRE Category?

- What if there were no sensation loss, no other findings (i.e., spasm, non-uniform ROM, no LOMSI, etc)?
 - DRE I = 0 %
- What if there was 2cm atrophy on the right calf?
 - DRE III = 10 %
- What if the fusion failed and there was 6mm translation?
 - DRE IV = 20 %
- If atrophy from radiculopathy AND 6mm translation?
 - DRE V = 25 %



Cervicothoracic – DRE IV

Loss of Motion Segment Integrity

OR

Multilevel Neurologic Compromise

- Differentiators
 - Loss of motion segment integrity
 - Bilateral or multi-level radiculopathy (one root each side or two or more roots the same side)
- Structural Inclusions
 - Compression fracture > 50%
 - Multilevel motion segment structural compromise (multilevel fractures/dislocations)
- 25% impairment



Cervicothoracic – DRE V

Severe Upper Extremity Neurological Compromise

- Differentiators
 - Total single level loss or severe multilevel loss
 - Requires use of external functional or adaptive device
- Structural Inclusions
 - Structural compromise with severe upper extremity motor compromise
- 35% impairment



Cervicothoracic – DRE VI, VII and VIII

- **REMEMBER:**
 - You must **COMBINE** impairment from Category VI, VII and VIII, with appropriate impairment from Category II thru V
- These categories of injury usually must have significant structural damage to cause the higher degrees of neurologic injury
- Neurologic injury is at the SPINAL CORD level
- Cervical injury *and* long tract signs
 - **Long tract signs** = hyperreflexia, clonus, Babinski + sensory / motor changes



Cervicothoracic - DRE Category VI

"Cauda Equina Like" Syndrome Without Bowel or Bladder

- Differentiators
 - Bilateral lower extremity neurological impairment
 - No bowel or bladder
 - Example = Central cord syndrome
- Structural Inclusions
 - None
 - If patient does not require ambulatory assistive device placed in DRE V (page 105)
 - Must combine with most appropriate II thru V
- 40% impairment



Cervicothoracic - DRE Category VI

“Cauda Equina Like” Syndrome With Bowel or Bladder

- Differentiators
 - Severe lower extremity compromise
 - Bowel or bladder involvement requiring assistive devices
- Structural Inclusions
 - None
 - Must combine with appropriate II thru V
- 60% impairment



Cervicothoracic – DRE VIII

Quadriplegia / Tetraplegia

- Differentiators
 - Complete loss of or near complete loss of lower extremity function
- Structural Inclusions
 - None
 - Must combine with appropriate II thru V
- 75% impairment

Thoracolumbar

- Rate by the **same methodology** as the cervicothoracic spine
- Spinal Cord Involvement = ***Paraplegia***
- IF there is spinal cord involvement, categories VI, VII, VIII combine with structural injury defined by Categories II – V



Cervicothoracic / Thoracolumbar

- Refer to summary Tables:
 - 73 – page 110 Cervicothoracic
 - 74 – page 111 Thoracolumbar
- These show how the DRE VI to VIII Combine with the DRE II to V
 - **43 % to 84 % for Cervicothoracic**
 - **38 % to 76 % Thoracolumbar**
- *LS spine DRE II – VIII are stand alone IR. DO NOT COMBINE WITH OTHER DRE.*

DRE
Categories
IV - VIII

Any Questions?

Nerve Injury, potentially associated with Spine Injury

- Chapter 4 (pages 150-152) address some areas of nerve injury potentially associated with Spine
- Intercostal – Sensory or motor Max 2 % per nerve
- Table 23 – “Spinal Nerves in the Head and Neck Region”
- Table 24 – “Inguinal and Perineal”

Nerve Injury, potentially associated with Spine Injury

- Associated nerve Injury
- Intercostal / Table 23 / Table 24
- Take the MAX value and multiply by Tables in Chapter 4 on page 151 to obtain the final IR:
 - Table 20 – Sensory
 - Table 21 - Motor



Pelvis

Section 3.4 – page 131

- Table is based on healed fractures.
- IR accrues only with displacement of the healed fracture and with or without residuals, dependent on the location.
- Some pelvic fractures are also addressed in lower extremity DREs (Table 64)
- SI joint issues?



Spinal Cord Injury

Section 4.3

Can occur without injury to the structure of the boney spinal column. In this case, – Use Chapter 4 (4.3) – pages 147-149.

- Examples: Epidural Hematoma, Transverse Myelitis, Infections
- Six areas of function (7 tables)
- If multiple areas are involved, *COMBINE* the values.



Spinal Cord Injury

- 4.3a – Station and Gait (Table 13) #
- 4.3b – Use of Upper Extremity (Tables 14 and 15)
- 4.3c – Respiration (Table 16)
- 4.3d – Urinary Bladder Dysfunction (Table 17)
- 4.3e – Anorectal Dysfunction (Table 18)
- 4.3f – Sexual Functioning (Table 19)

*If there was a Cauda Equina Injury that impaired the sacral Root, without affecting gait, then use Tables 17 – 19.



MORE...

- What if there was a lower thoracic or lumbar spinal column injury (i.e. Burst Fracture with retropulsed fragments to sacral roots)
 - With Bowel and bladder changes
 - No lower extremity weakness?
- It Would not meet DRE VI
 - However, you may pick the highest DRE structural category, and then combine with the bowel / bladder / erectile function as per Spinal Cord in section 4.3

Don't Forget!

Please submit your evaluation for the Spine MMI/IR presentation.
Chiropractors also submit your Overall Course evaluations.

<https://www.tdi.texas.gov/wc/dd/training.html>

Please submit your attestation form for the pre-recorded presentations.

<https://www.tdi.texas.gov/wc/dd/documents/ddattestation.pdf>

Remember to check out the article,
*"Nomenclature and Classification of Lumbar
Disc Pathology"* at:

http://hbtinstitute.com/files/SPINE2001_Disk_Nomenclature.pdf

Thank you