

Designated Doctor Case-Based Webinar Module 3

Upper Extremity MMI IR

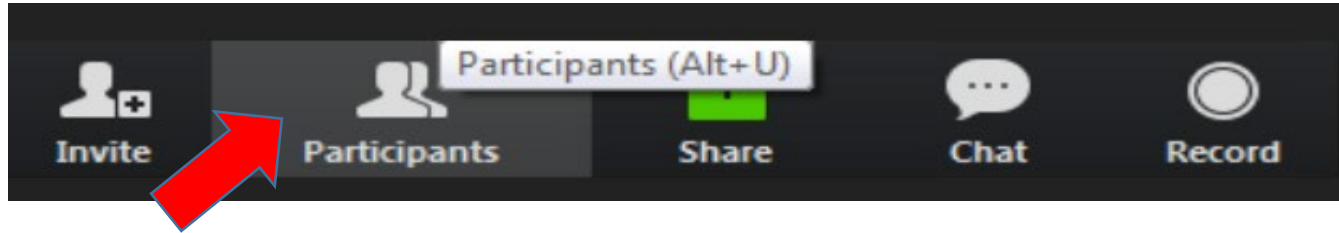
Disclaimer

The material presented in this workshop is made available by the Texas Department of Insurance - Division of Workers' Compensation (TDI-DWC) for educational purposes only. The material is not intended to represent the only method or procedure appropriate for the medical situations discussed. Rather, it is intended to present an approach, view, statement, or opinion of the faculty, which may be helpful to others who face similar situations.



Housekeeping

At the bottom of your screen, click to turn on the participant list:



Ensure your name (not phone # or initials) is shown on the Participant List for CME and attendance purposes. If not, do the following to rename:

Hover over your current sign in and two boxes appear

Click on the Rename box

Type in your first and last name



Asking questions

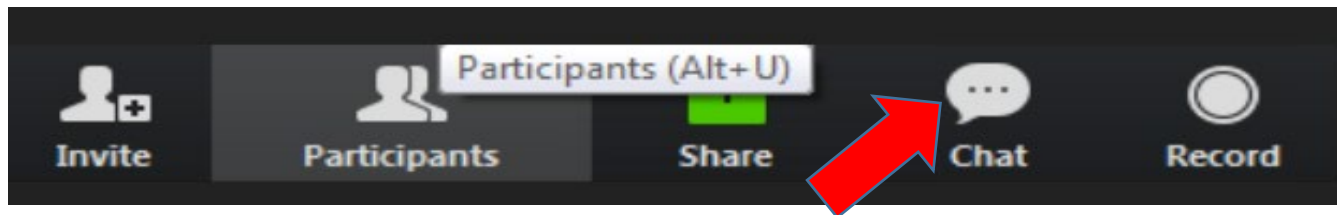
Please mute your phone/VOIP audio connection

All attendees will be muted during the presentation and submit questions via Chat

Attendees may be unmuted at the request of the monitor or instructor for clarification or further discussion

Asking questions

You will find the Chat feature to the right of the participants list.



As the instructor goes through the course they will ask for questions via chat at the end of a case, or after a concept has been explained.

You may type your questions into Chat. The Chat monitor may answer your question in Chat, or have the instructor answer the question verbally.

Upper Extremity MMI/Impairment Rating

Combined Values for Impairment Rating

Each organ system/body area should be expressed as a whole person impairment, then

- Whole person impairments should be **combined** using the Combined Values Chart (pp. 322 – 324)
- “Combining” assures that the impairment can’t exceed 100%. It reduces the remaining portion of the whole person that is available for the second impairment
- Example 40% c/w 40% (of the remaining 60%) = 64%

Combining 3 or More Impairment Values

- “If three or more impairment values are to be combined, select any two and find their combined value as above. Then use that value and the third value to locate the combined value of all. This process can be repeated indefinitely, the final value in each instance being the combination of all the previous values. In each step of this process, the larger impairment value must be identified at the **side** of the chart.” (page 322)

Combining 3 or More Impairment Values

- **Best practice - combine the largest % with the second largest %, then combine with third largest %, etc.**

Conflict between DWC Statutes/Rules and AMA *Guides*

**DWC Statutes/Rules
take precedence**

Combining values in the Upper Extremity

1. Combine joint to joint (exception: thumb joint to joint ratings are added)
2. Combine final joint ROM with nerve or other disorders at digit
3. Combine final joint ROM and nerve or other disorder for final upper extremity impairment
4. If rating both upper extremities, take each to whole person IR value, THEN combine

Upper Extremity MMI/IR

- 42-year-old female school attendance clerk developed carpal tunnel syndrome
- Treated surgically and has reached MMI
- At MMI, reported improvement, but continued to complain of mild to moderate pain and numbness in right thumb and index finger
- Performs job duties without noticing symptoms

Upper Extremity MMI/IR Case 1

Physical Examination at MMI

- Full range of motion of thumb, fingers and wrist
- Manual muscle testing of thenar and lumbrical, wrist flexor and extensor muscles reveals 5/5 strength

Upper Extremity MMI/IR Case 1

Physical Examination at MMI (cont'd)

- Two-point discrimination is 6 mm over all parts of hand; except palmar radial and ulnar portions of thumb and palmar radial and ulnar portions side of index finger, where she has 12 mm two-point discrimination

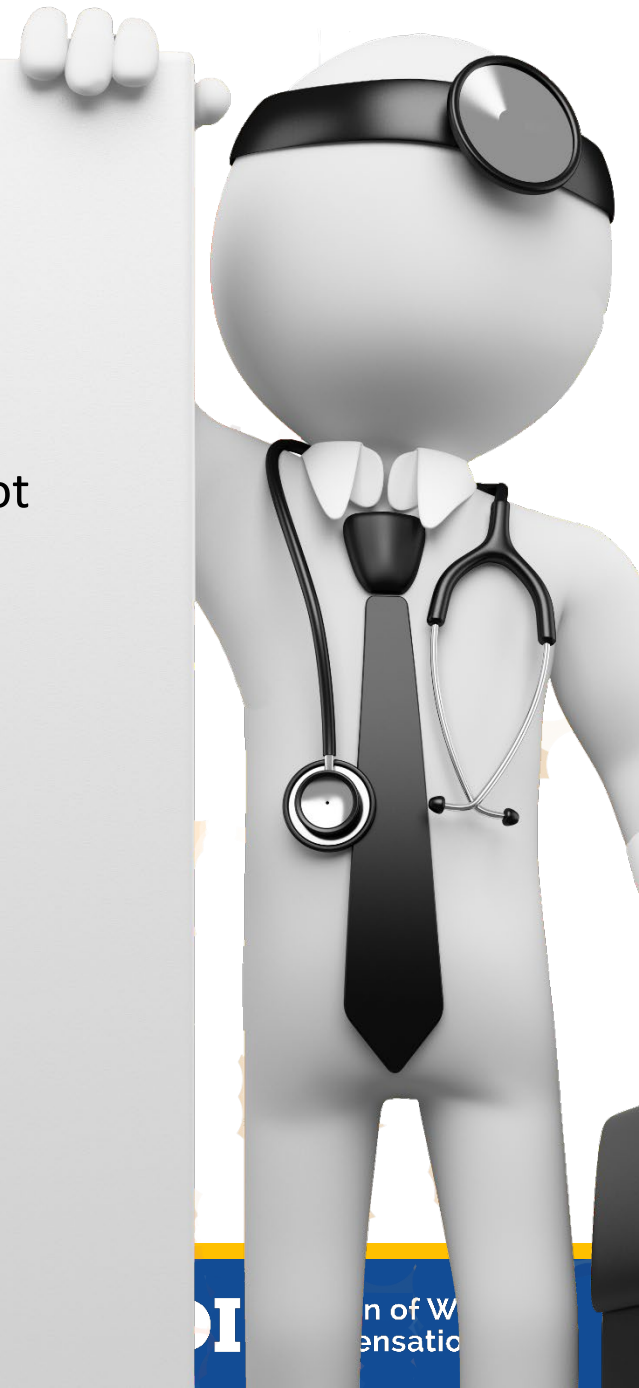Upper Extremity MMI/IR Case 1


- On date of MMI, what is whole person IR?
- A. 4%
- B. 7%
- C. 8%
- D. 14%



Upper Extremity MMI/IR Case 1

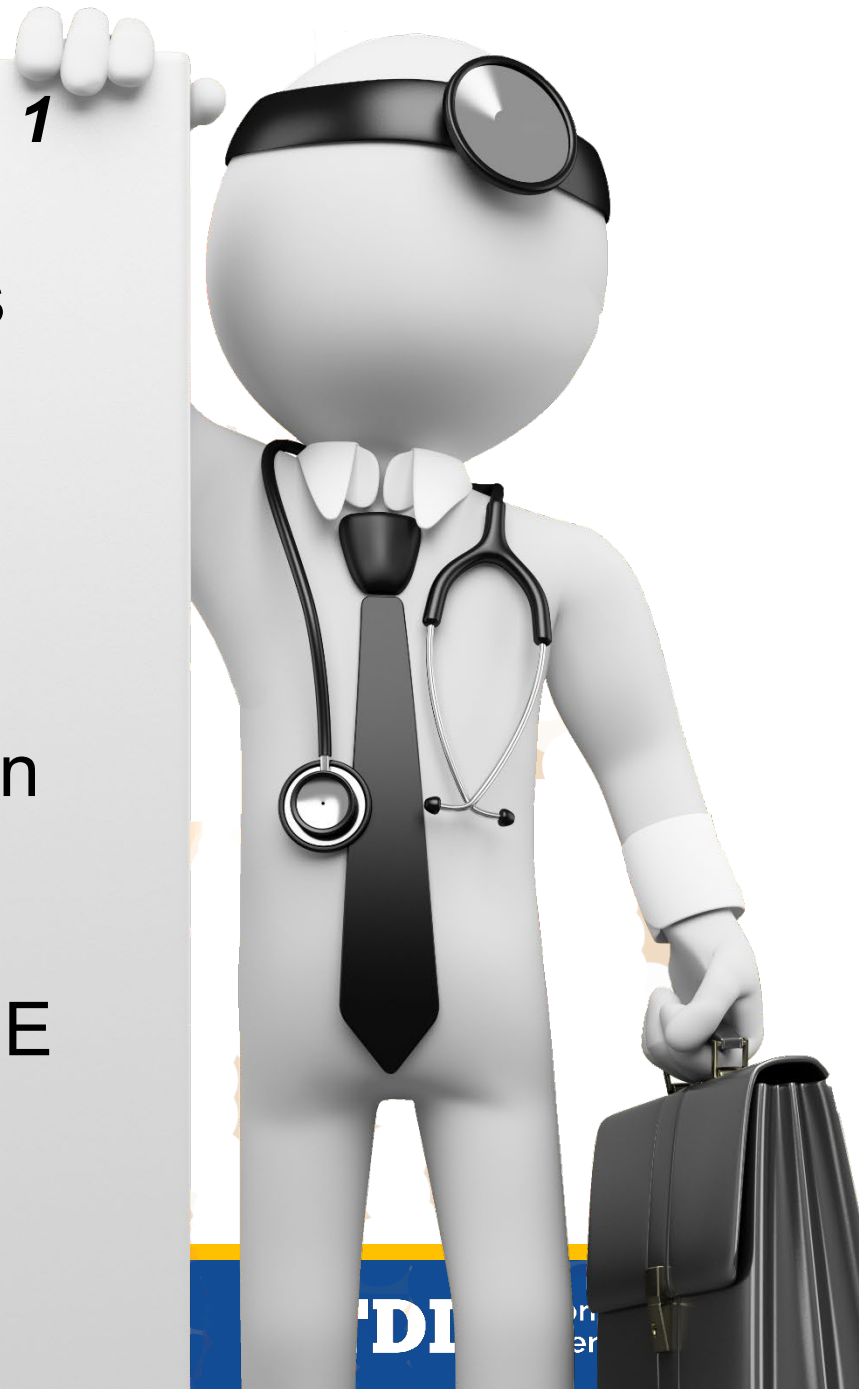- **4% WP**
- What is the condition?
 - CTS with partial median nerve sensory deficit, not digital nerves
- Median nerve (below mid-forearm)
 - Table 15 (page 54)
 - Anatomic sensory loss – radial and ulnar palmar aspects of thumb and index finger
 - Radial palmar digital of thumb, 7% UE
 - Ulnar palmar digital of thumb, 11% UE
 - Radial palmar digital of index finger, 5% UE
 - Ulnar palmar digital of index finger, 4% UE
 - 27% UE







Upper Extremity MMI/IR Case 1

- Severity of sensory loss
 - Table 11, page 48
 - Grade 2 forgotten with activity
 - 1% to 25%
 - “Use maximum value” in example
 - 25% in this case
 - $25\% \times 27\% \text{ UE} = 7\% \text{ UE}$
 - $7\% \text{ UE} = 4\% \text{ WP}$
 - Table 3, page 20









Questions About Upper Extremity MMI/IR Case1?



Upper Extremity MMI/IR Case 2

- 22-year-old bartender lacerated right index finger at MP joint; in emergency room found to have complete transection of radial digital nerve and partial transections of flexor tendons
- Underwent surgical repair, followed by rehabilitation and reaches MMI

Upper Extremity MMI/IR Case 2

- At MMI:
 - 2 point discrimination is 5 mm over ulnar palmar aspect of index finger
 - 2 point discrimination is greater than 15 mm distal to the laceration at MP joint on radial palmar aspect of index finger

Upper Extremity MMI/IR Case 2

- Range of motion DIP joint extension to minus 30°; flexion to 40°
- Range of motion PIP joint extension to minus 30°; flexion to 50°
- Range of motion MP joint extension to minus 10°; flexion to 60°

Upper Extremity MMI/IR Case 2

On date of MMI, what is the whole person IR?

- A. 7%
- B. 8%
- C. 14%
- D. 15%



Upper Extremity MMI/IR Case 2


8% WP

- Index finger ROM
- Sensory loss radial digital nerve index finger






DIP, PIP & MP Measurements





DIP, PIP & MP Measurements



Upper Extremity MMI/IR Case 2

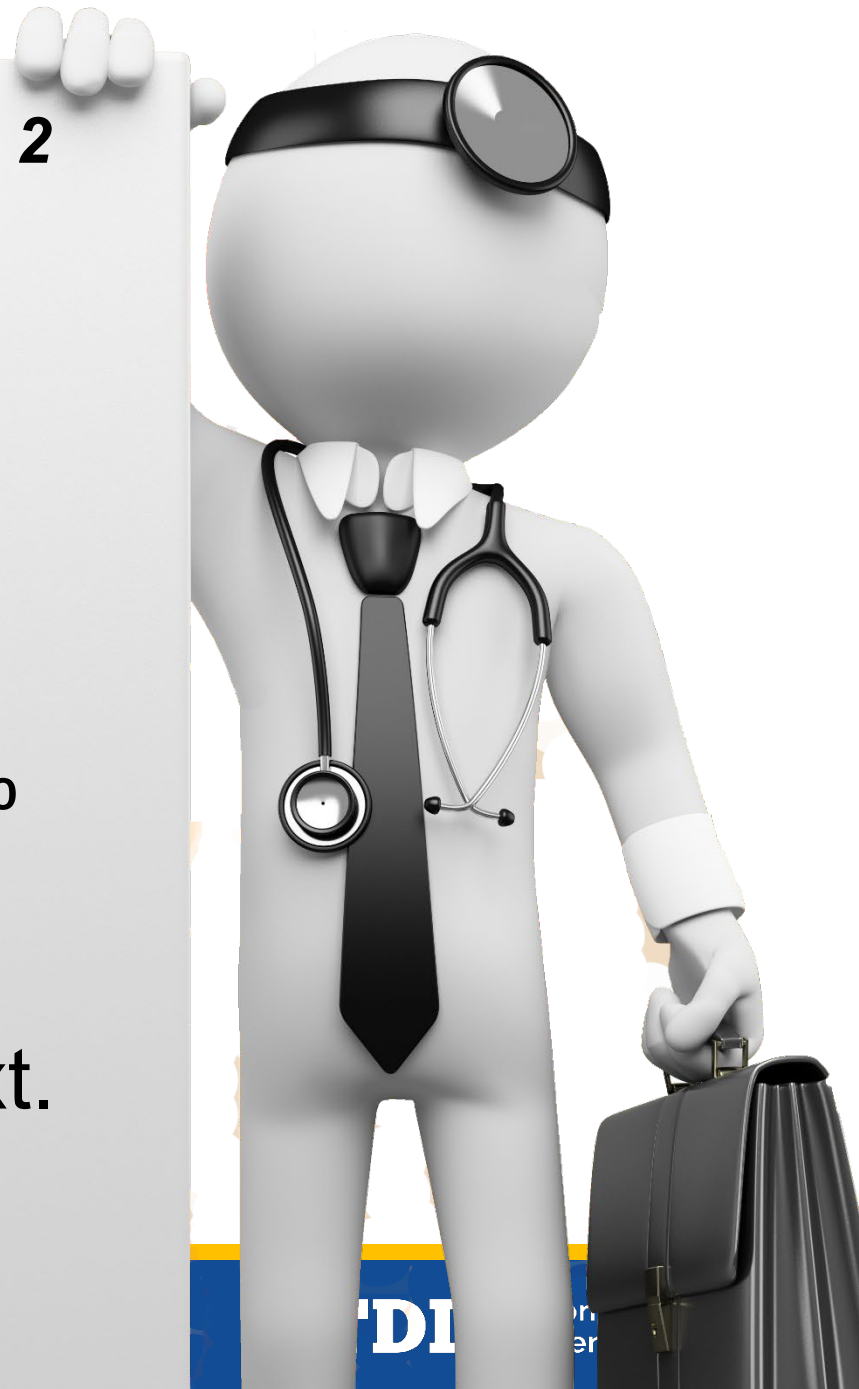Figure 23, page 34

- MP flexion = 60°
= 17% index finger

Figure 23, page 34

- MP extension = -10°
= 7% index finger


Add MP flexion + MP ext.
 $17\% + 7\%$
= 24% index finger






Upper Extremity MMI/IR Case 2

MP: Figures 22 and 23, Page 34



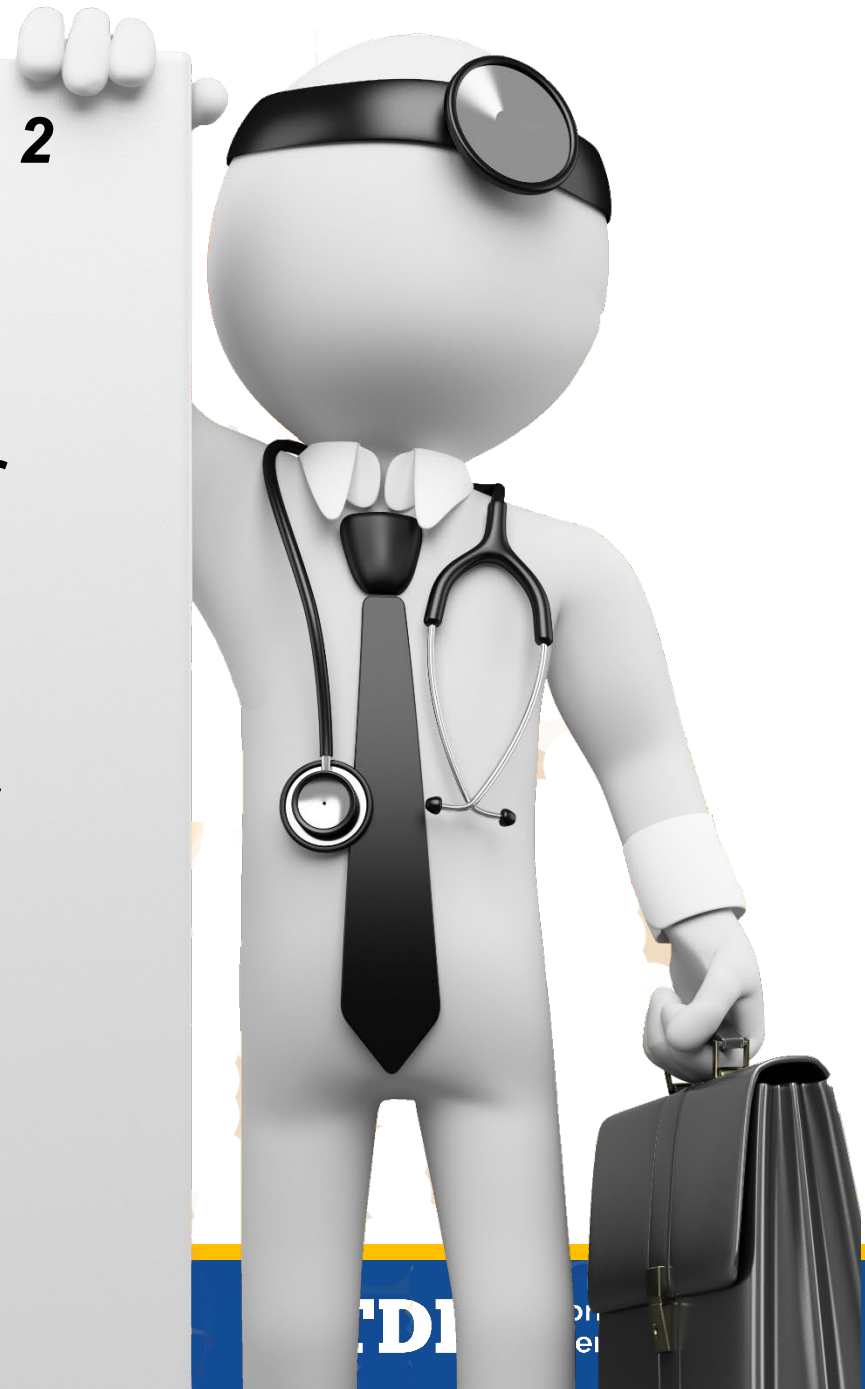

Upper Extremity MMI/IR Case 2
Figure 23, Page 34



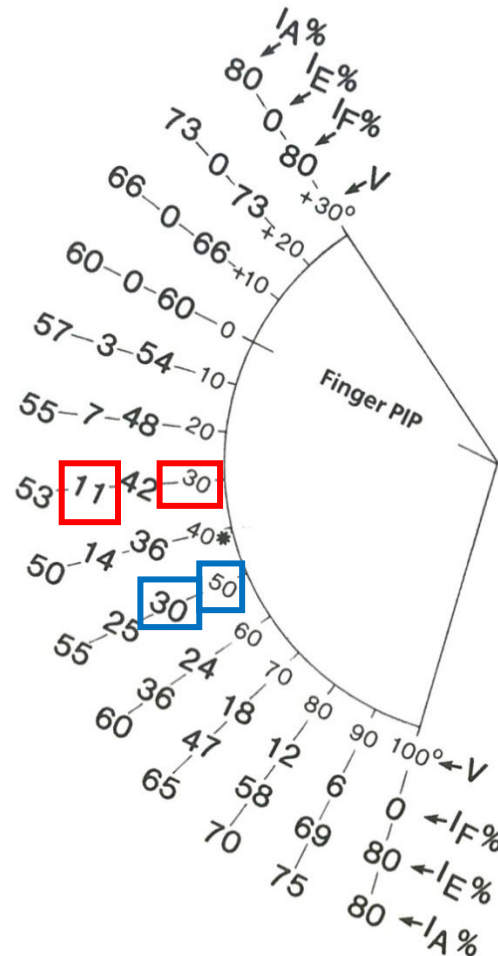
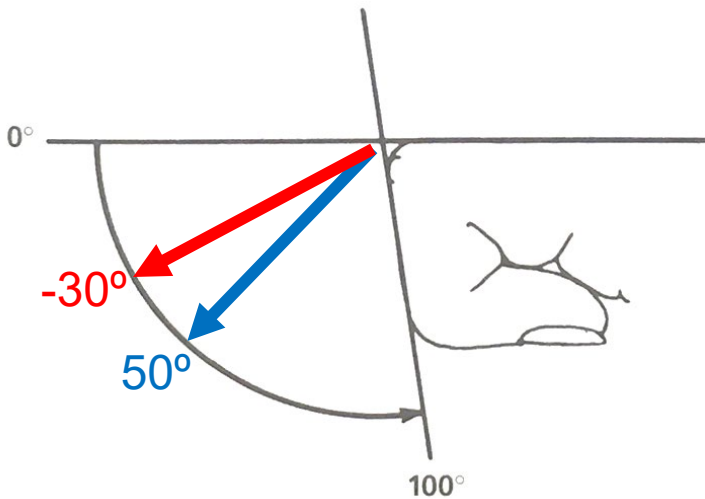
Upper Extremity MMI/IR Case 2

- Figure 21, page 33
 - PIP flexion = 50°
 - = 30% index finger
- Figure 21, page 33
 - PIP extension = -30°
 - = 11% index finger
- **Add** PIP flexion + PIP extension
 - 30% + 11%
 - = 41% index finger

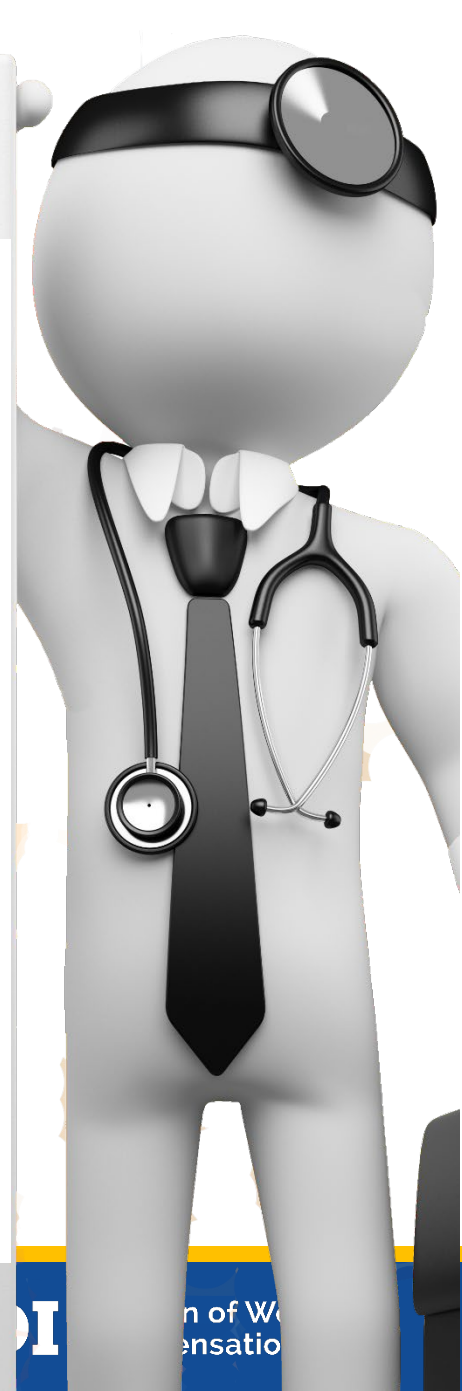

Upper Extremity MMI/IR Case 2

PIP: Figures 20 and 21, Page 33



$$11\% + 30\% = 41\% \text{ PIP}$$



Upper Extremity MMI/IR Case 2

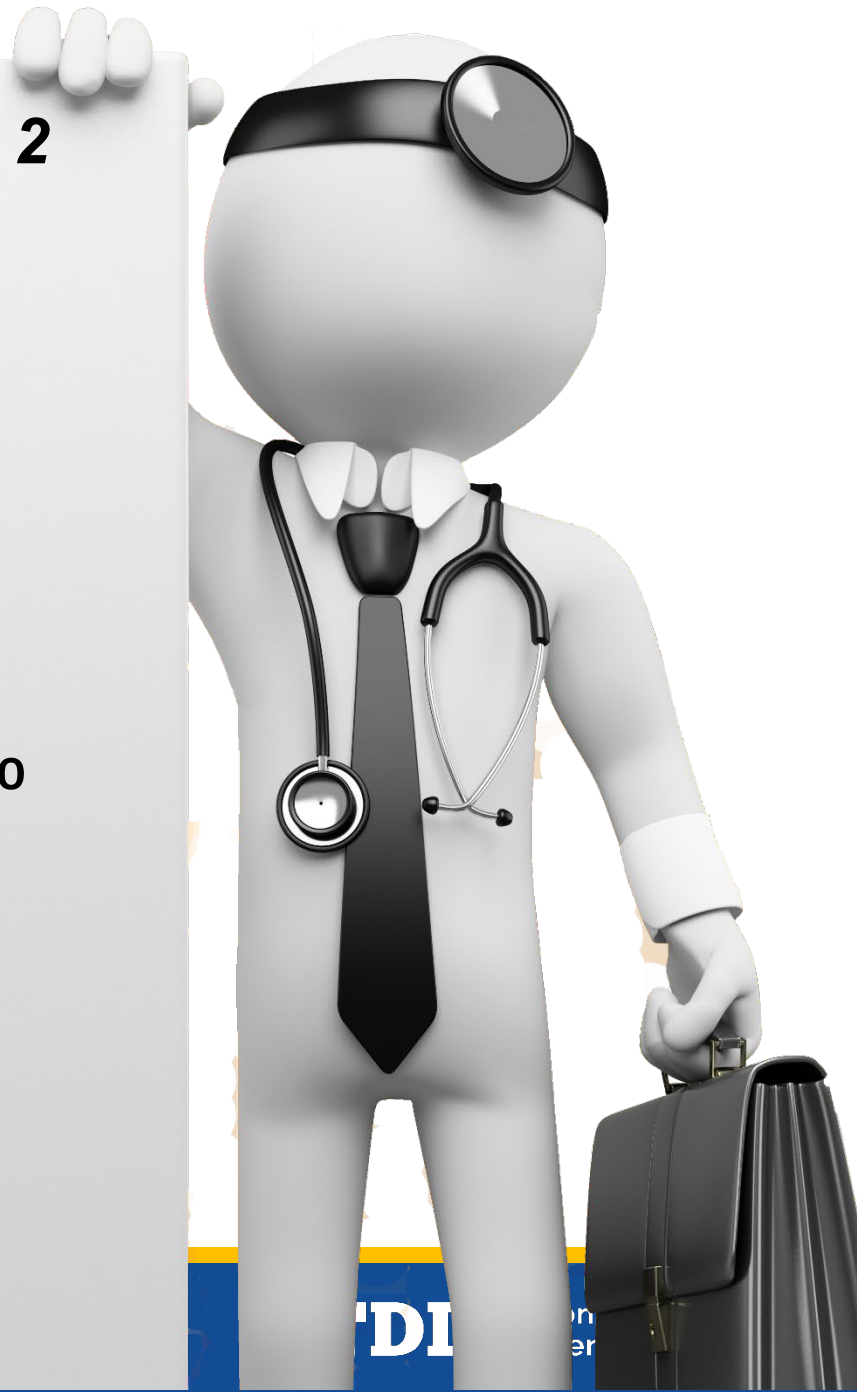Figure 19, page 32

- DIP flexion = 40°
= 15% index finger

Figure 19, page 32

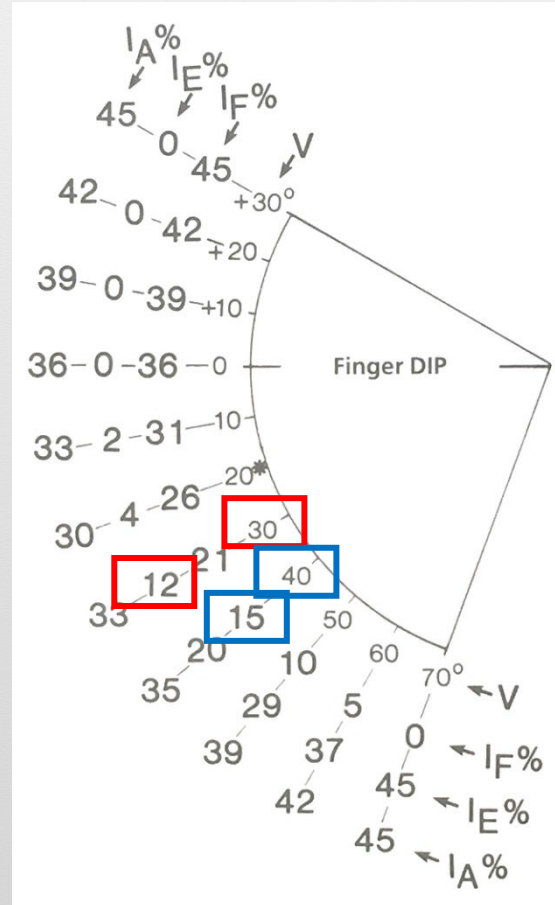
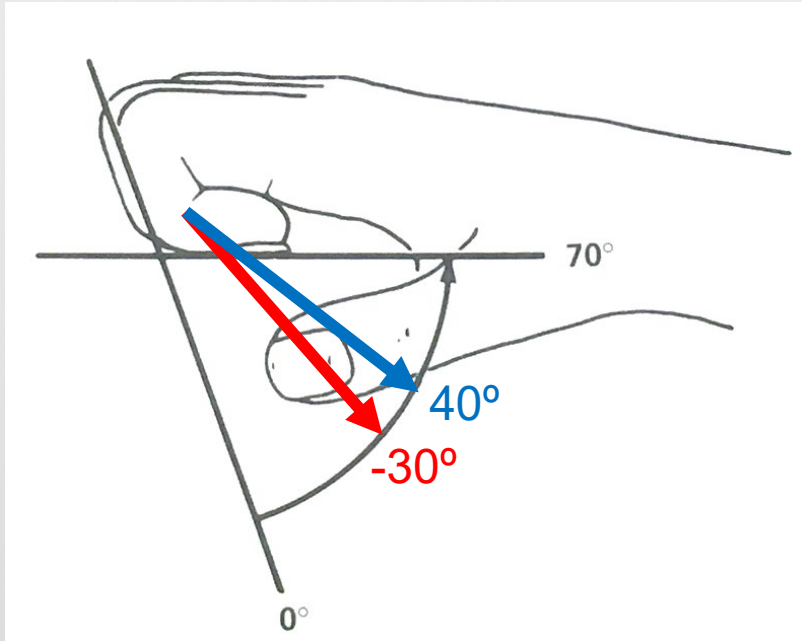
- DIP extension = -30°
= 12% index finger

Add DIP flex. + DIP ext.
 $15\% + 12\%$
= 27% index finger

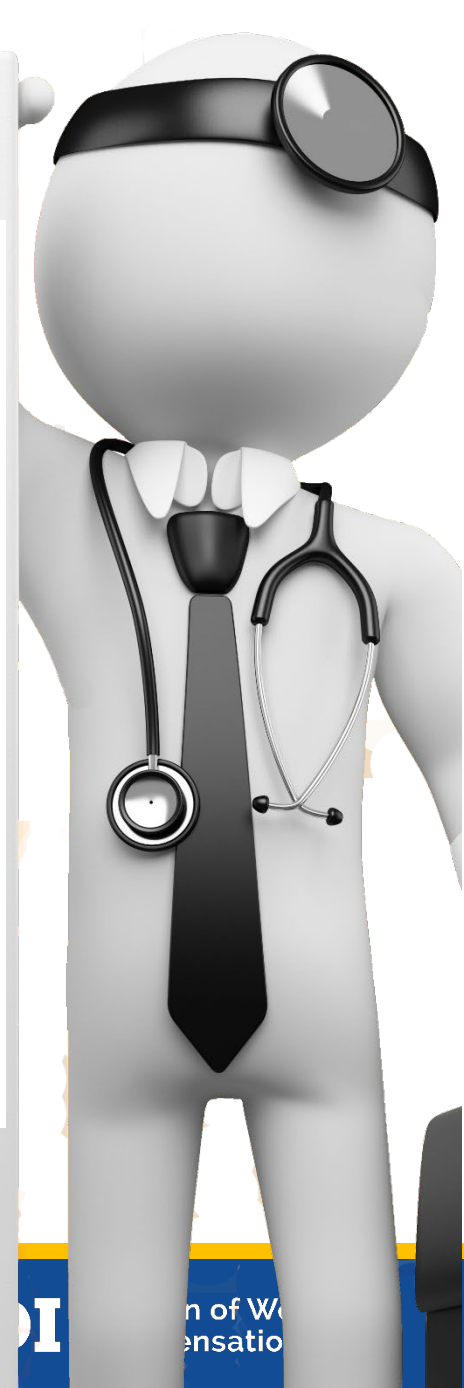

Upper Extremity MMI/IR Case 2

DIP: Figures 18 and 19, Page 32



$$12\% + 15\% = 27\% \text{ DIP}$$



Upper Extremity MMI/IR Case 2

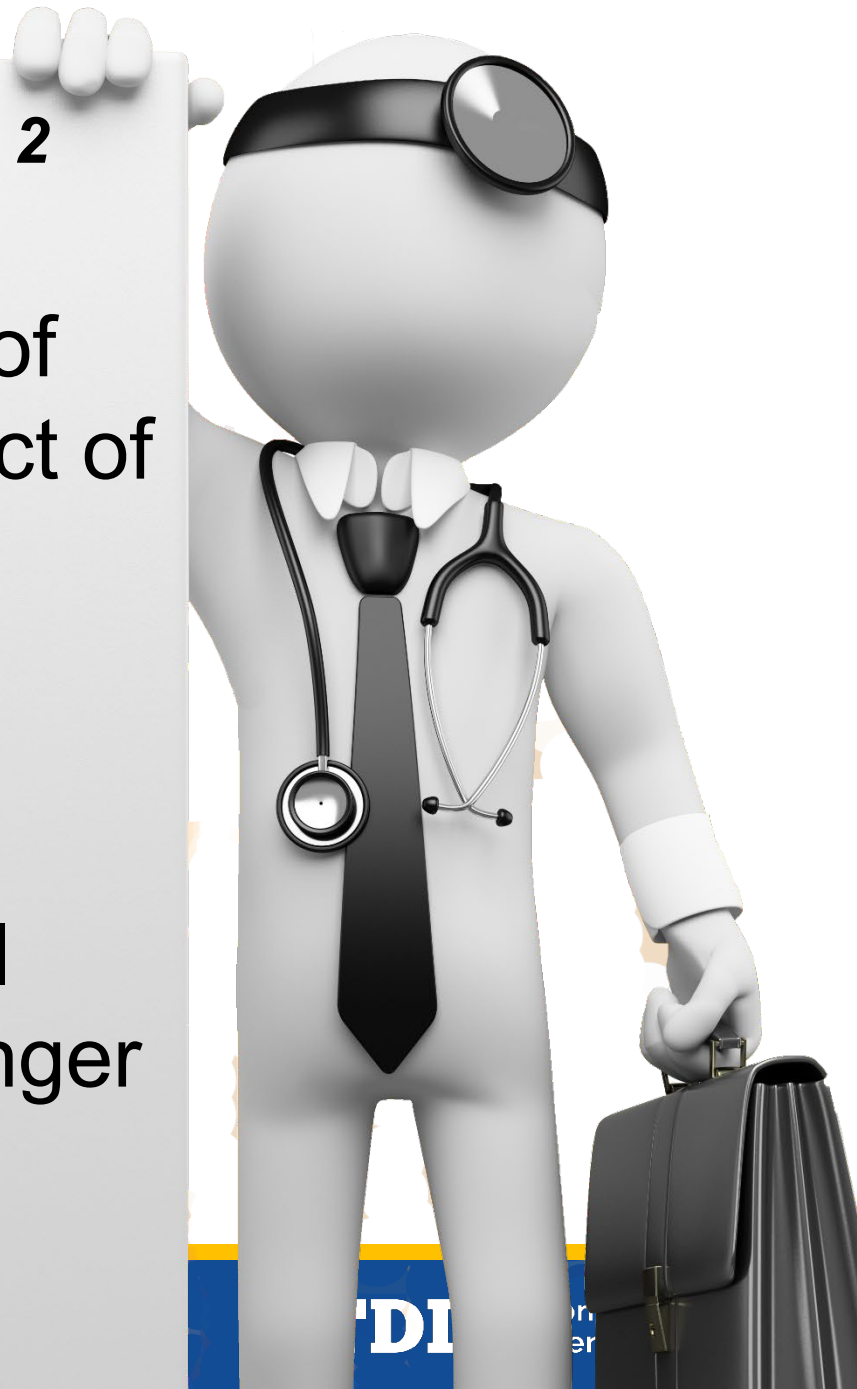- **Combine** MP, PIP, DIP ROM
 - MP = 24% index finger
 - PIP = 41% index finger
 - DIP = 27% index finger
- start with largest 2:
 - ROM = PIP 41% cw DIP 27% = 57%
 - 57% cw MP 24% = **67% index finger**
- **ROM = 67% index finger**
- Combine with sensory deficit for total loss of radial digital nerve of index finger distal to MP joint



Upper Extremity MMI/IR Case 2

Two point discrimination of
>15 mm over radial aspect of
from MP joint distally

- Table 9, page 31
- 100% length
- total loss radial digital
nerve = 30% index finger



Upper Extremity MMI/IR Case 2

Figure 17, Page 30

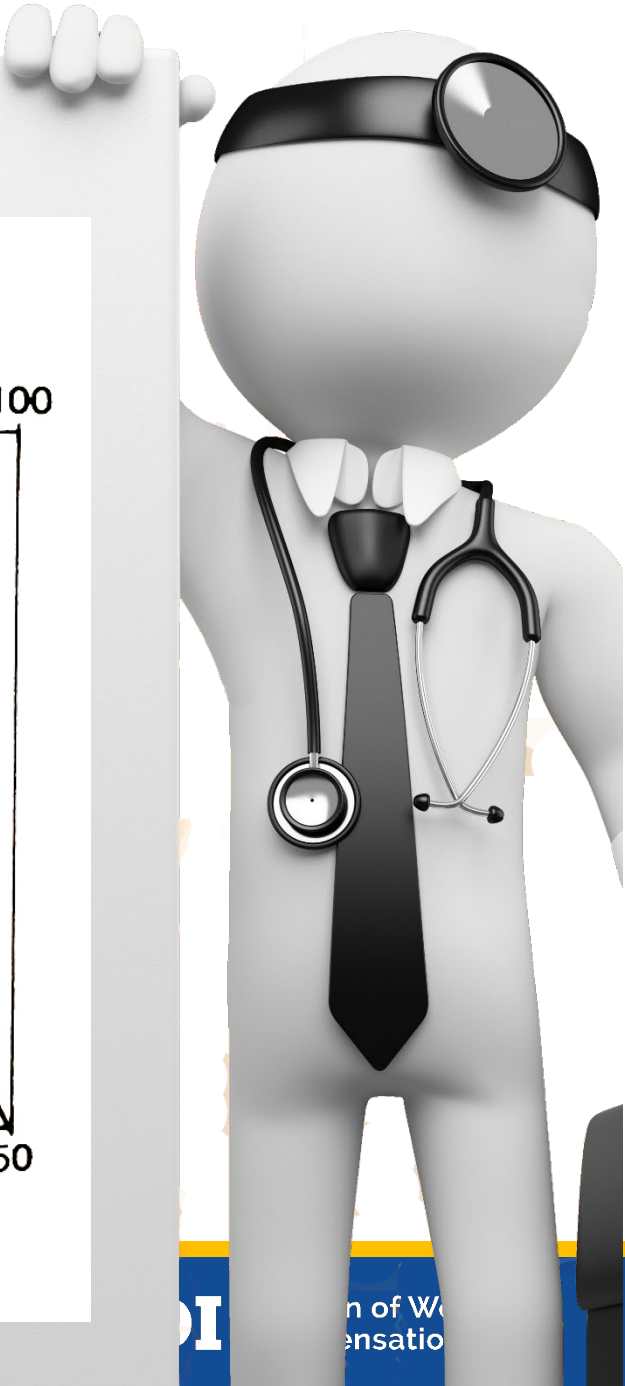
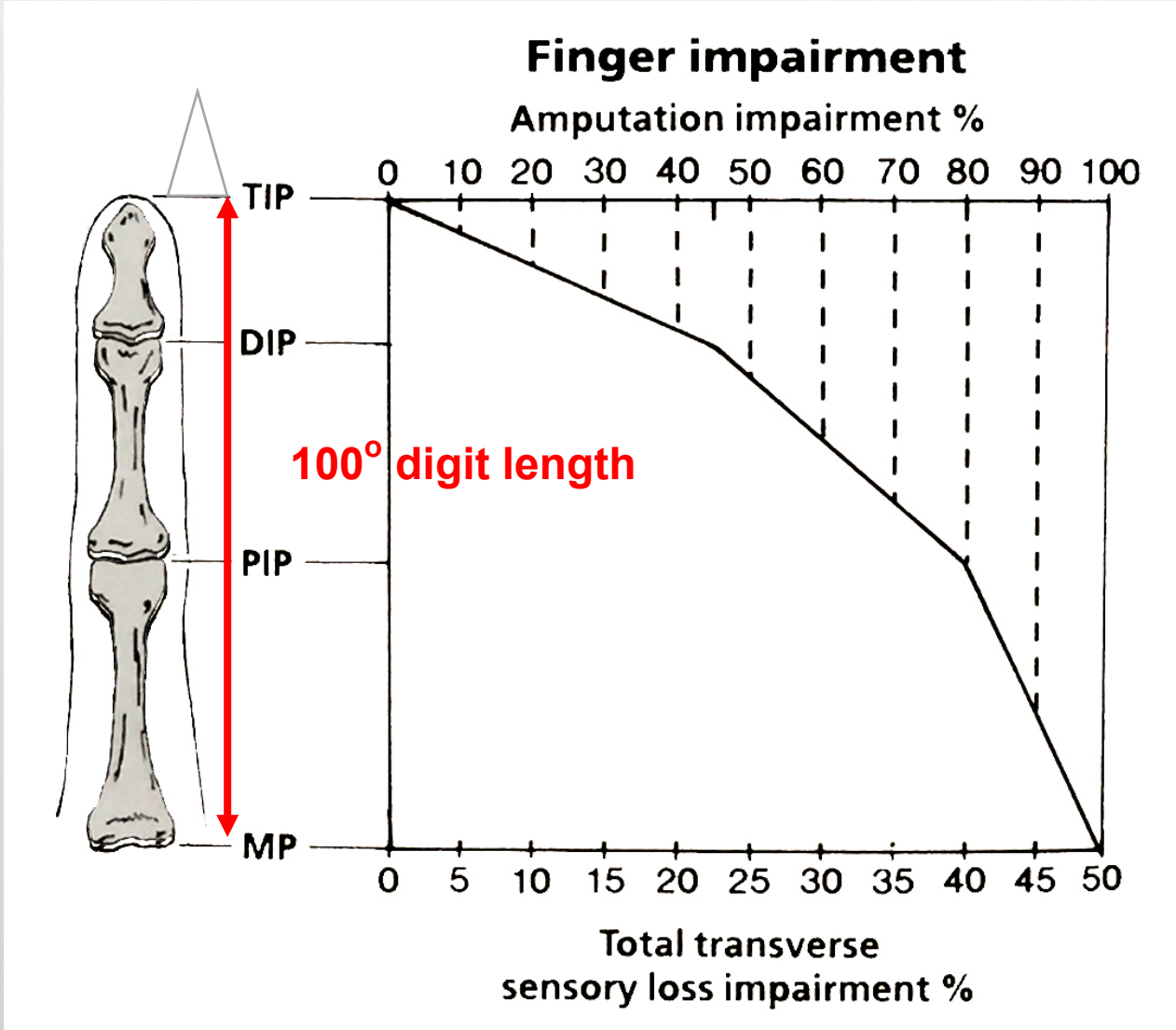
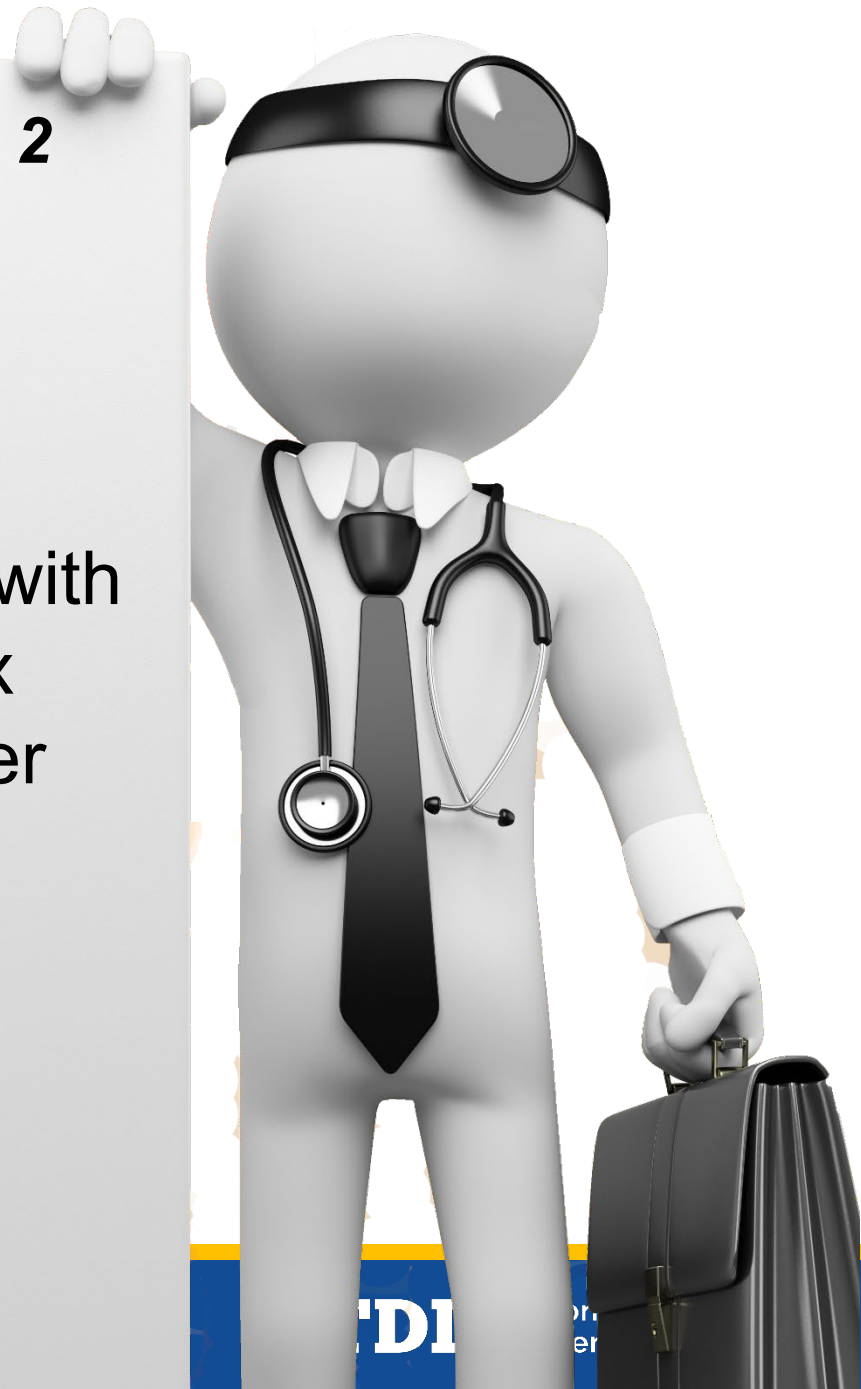

Table 9, Page 31

Percent of digit length	Longitudinal sensory loss (%)			
	Ulnar digital nerve		Radial digital nerve	
	Total loss	Partial loss	Total loss	Partial loss
100	20	10	30	15
90	18	9	27	14
80	16	8	24	12
70	14	7	21	11
60	12	6	18	9
50	10	5	15	8
40	8	4	12	6
30	6	3	9	5
20	4	2	6	3
10	2	1	3	2

Upper Extremity MMI/IR Case 2

- ROM = 67%
- Sensory loss = 30%
- Combine
 - ROM 67% index finger with Sensory loss 30% index finger = 77% index finger
- Convert
 - 77% index finger =
 - 15% hand; 15% hand =
 - 14% UE; 14% UE =
 - **8% WP**





Questions About Upper Extremity MMI/IR Case 2?



Upper Extremity MMI/IR Case 3

- IE falls sustaining Colles fracture/dislocation of distal radius
- Undergoes ORIF
- Completes post-op PT
- Reaches MMI

Upper Extremity MMI/IR Case 3

- DD Exam
 - Wrist ROM
 - flexion 50°
 - extension 20°
 - radial deviation 16°
 - ulnar deviation 17°
 - Elbow/Forearm ROM
 - pronation 50°
 - supination 50°
 - Wrist crepitation (constant) with active ROM
 - Normal sensation and strength

Upper Extremity MMI/IR Case 3

- On date of MMI, what is whole person IR?
 - A. 8%
 - B. 10%
 - C. 13%
 - D. 14%



Upper Extremity MMI/IR Case 3

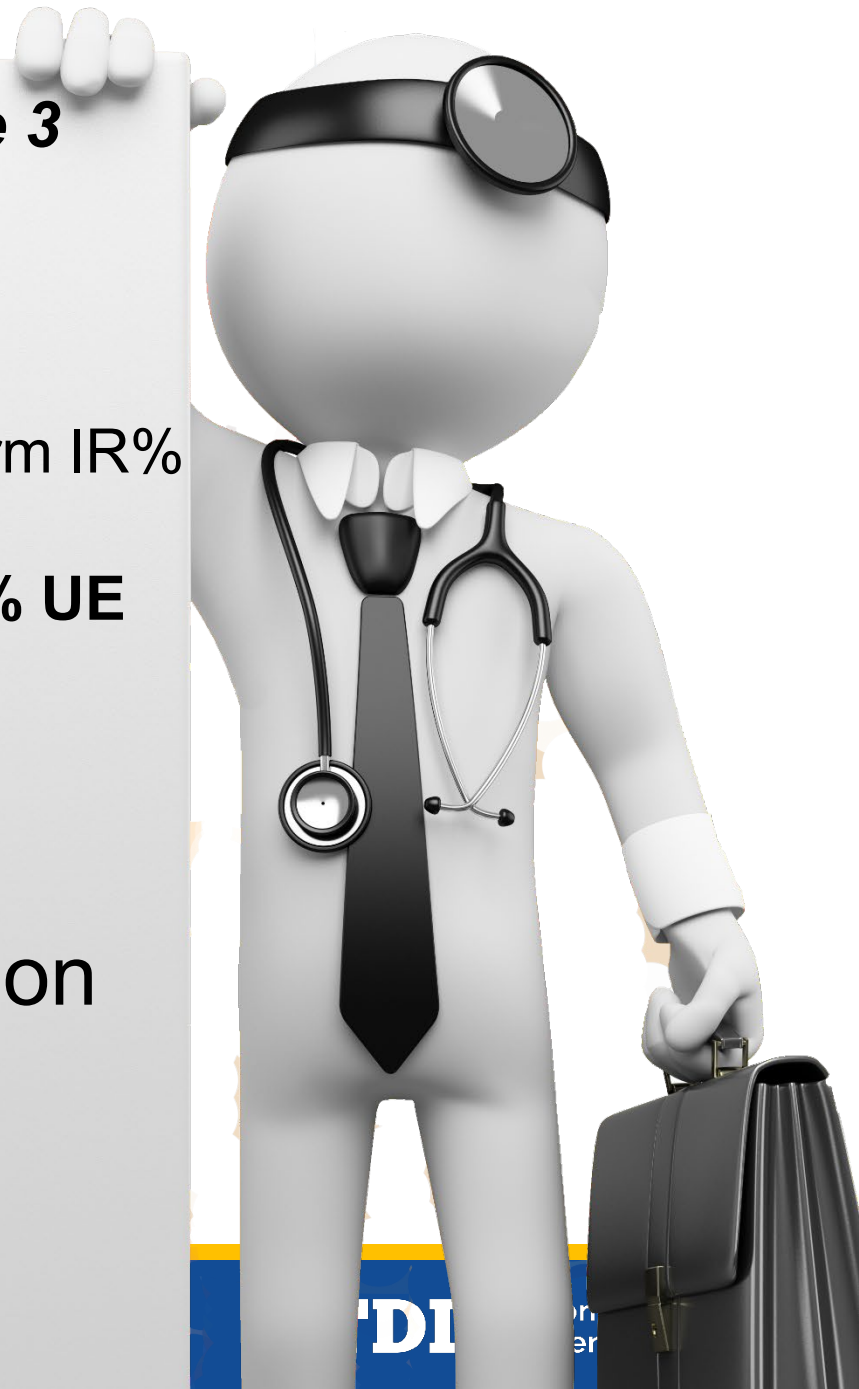8% WP

- Wrist ROM
 - flexion 50° = 2% UE
 - extension 20° = 7% UE
 - radial deviation 16° (rounds to 20°) = 0% UE
 - ulnar deviation 17° (round to 20°) = 2% UE
 - **Add** $2\% + 7\% + 0\% + 2\% = 11\%$ UE
- Elbow/Forearm ROM (see e.g. page 72)
 - pronation 50° = 2% UE
 - supination 50° = 1% UE
 - **Add** $2\% + 1\% = 3\%$ UE



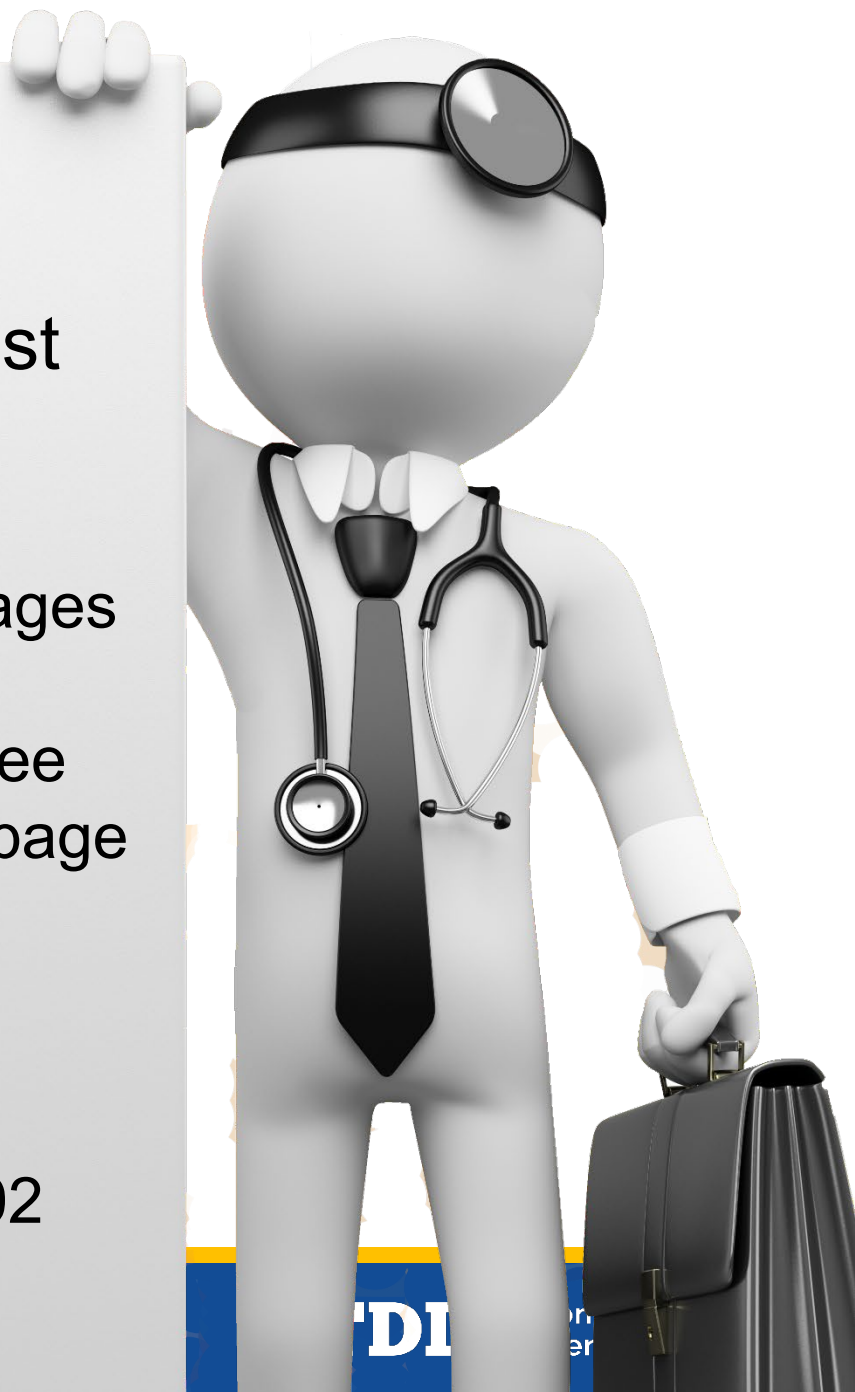Upper Extremity MMI/IR Case 3

- **Combine**
 - Wrist IR% With Elbow/Forearm IR%
 - Wrist 11% UE cw
 - Elbow Forearm 3% UE = **14% UE**
- **Convert**
 - 14% UE = **8% WP**
- **Don't combine crepitation with ROM**
 - page 59 above Table 19



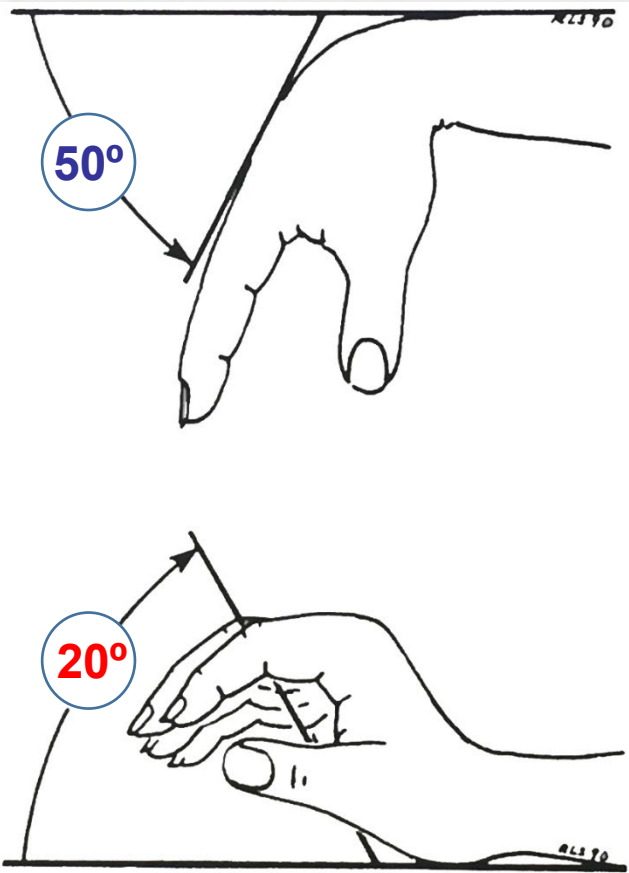
Rounding UE ROM

- Round UE ROM to nearest 10 degrees per written instructions
 - AMA Guides 4th edition, pages 25-44
 - also, page 15 (NOT 5 degree increments per Figure 29, page 38 wrist RD/UD)
- Appeals Panel Decision 022504-s
 - decided November 12, 2002

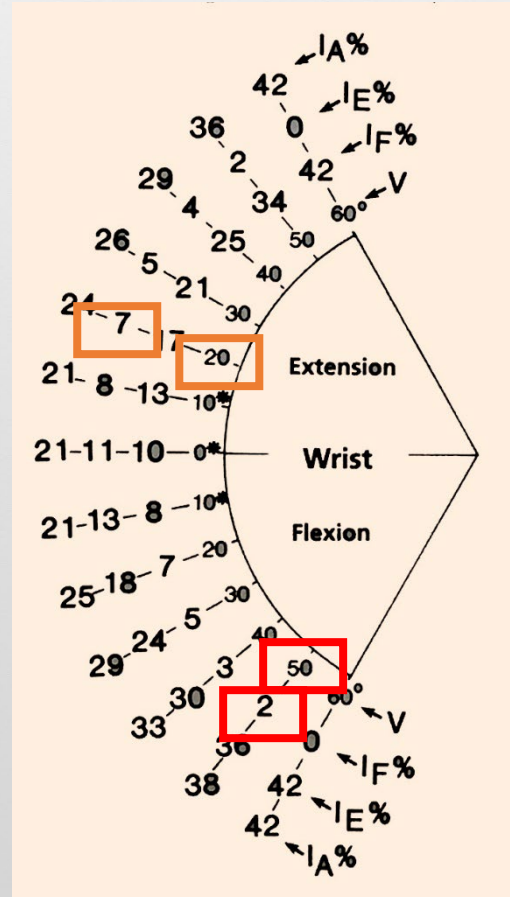


Upper Extremity MMI/IR Case 3

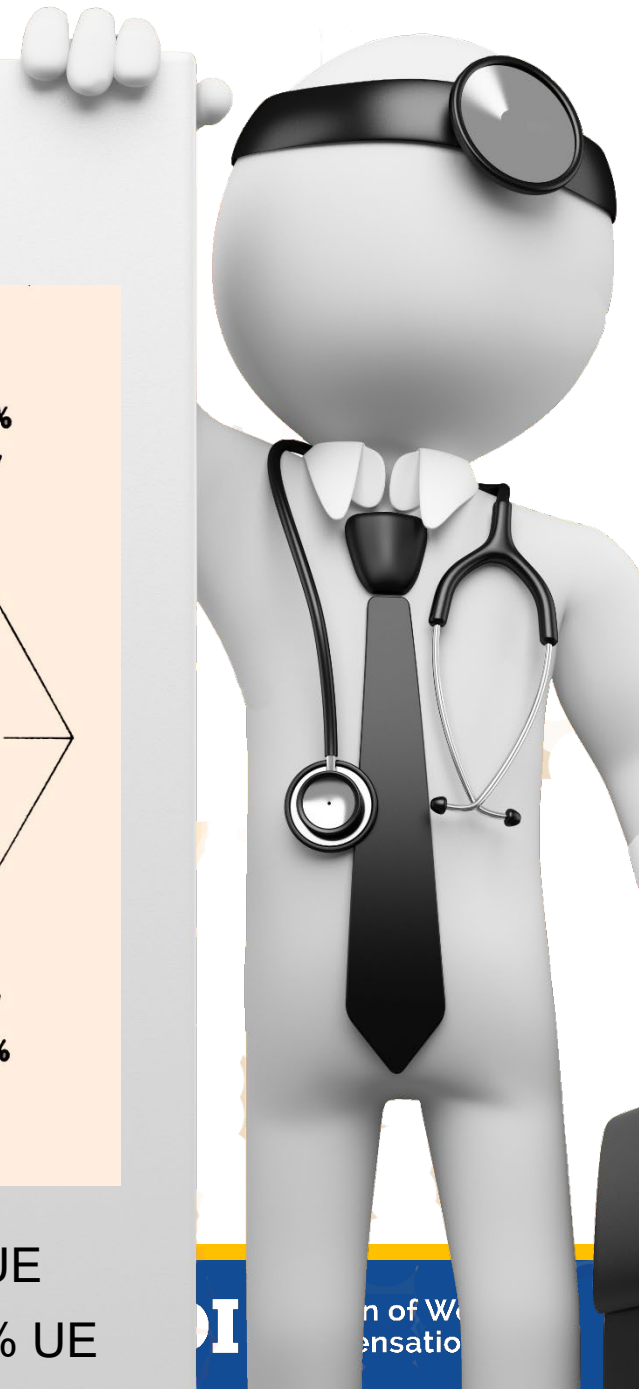
Figures 24 & 26, Page 36



Wrist Flexion = 50°
 Wrist Extension = 20°

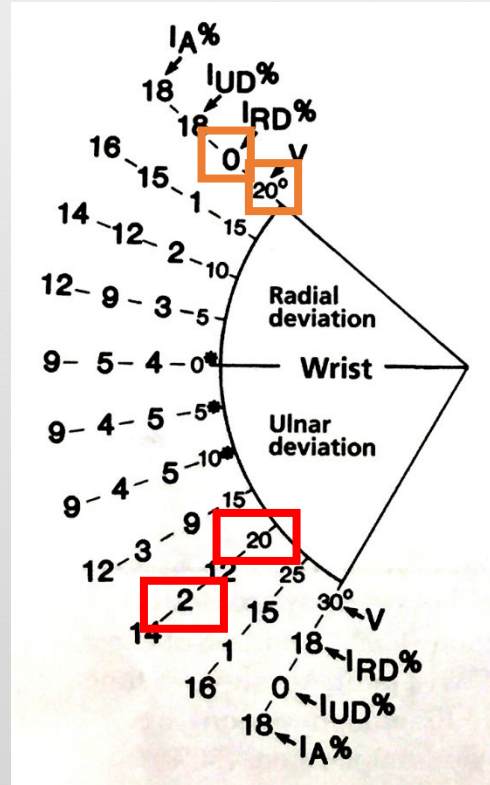
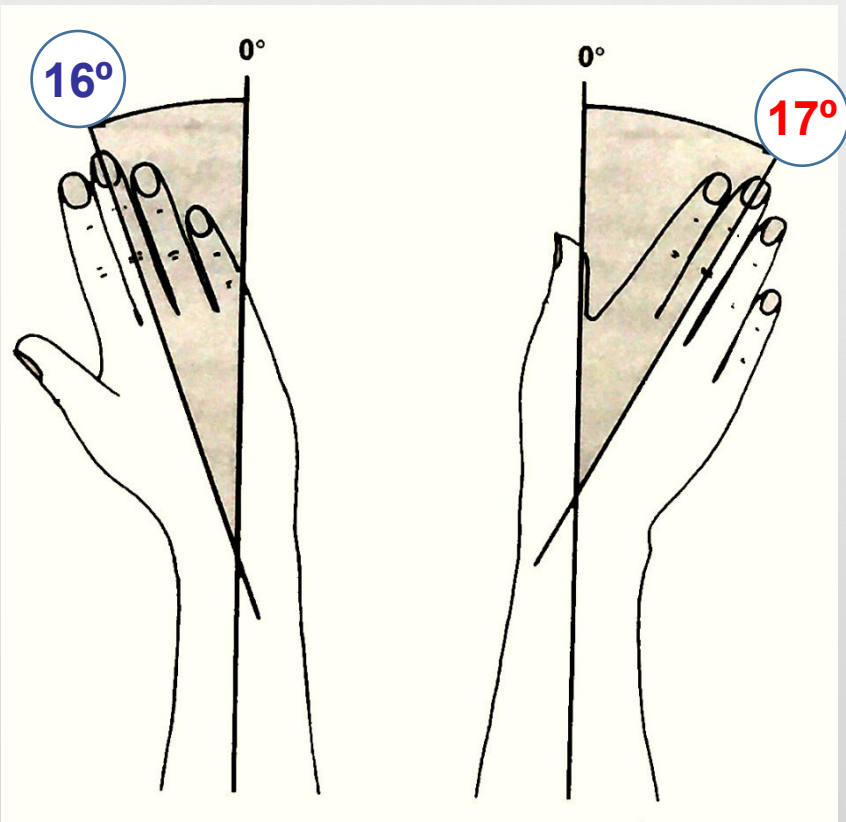


Wrist Flexion = 50° = 2% UE
 Wrist Extension = 20° = 7% UE



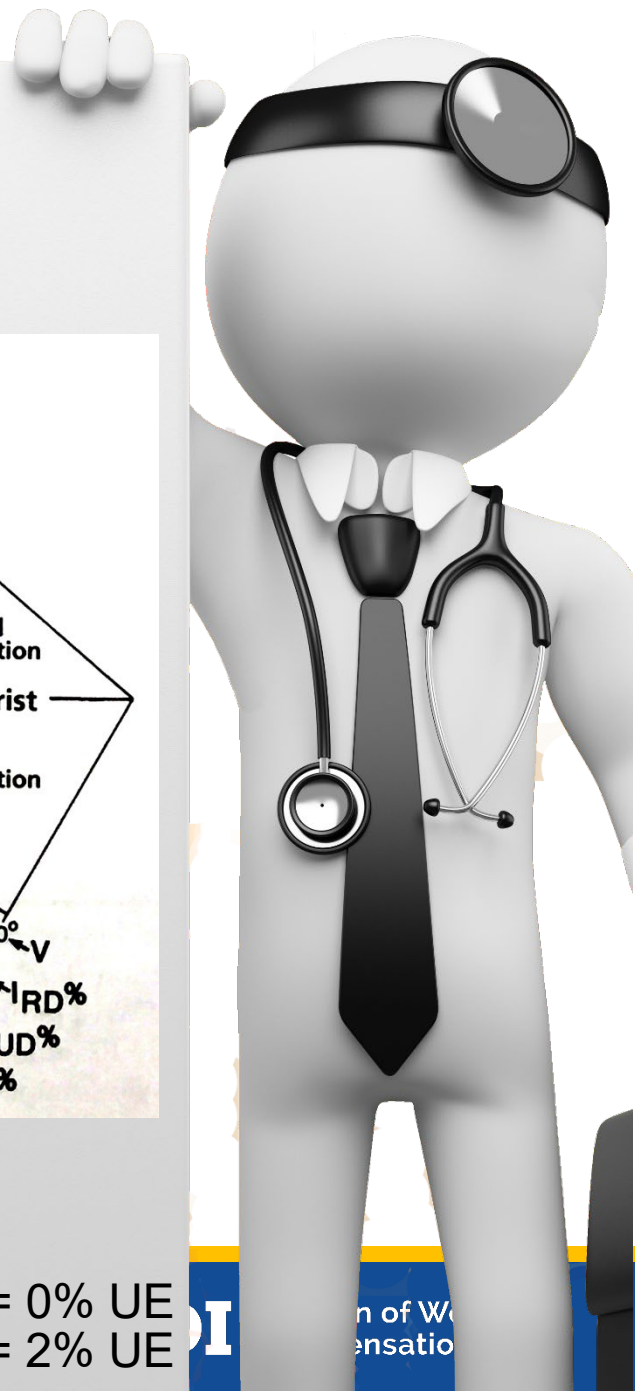
Upper Extremity MMI/IR Case 3

Figure 27, Page 37 and Figure 29, Page 38



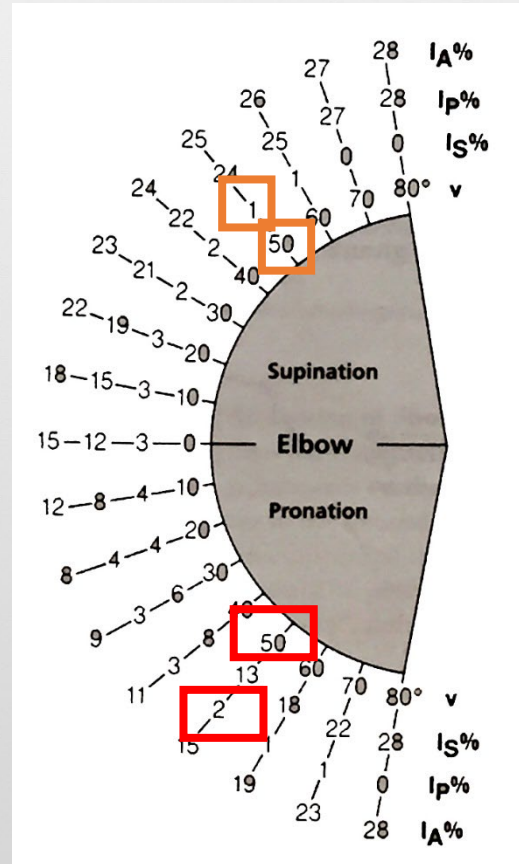
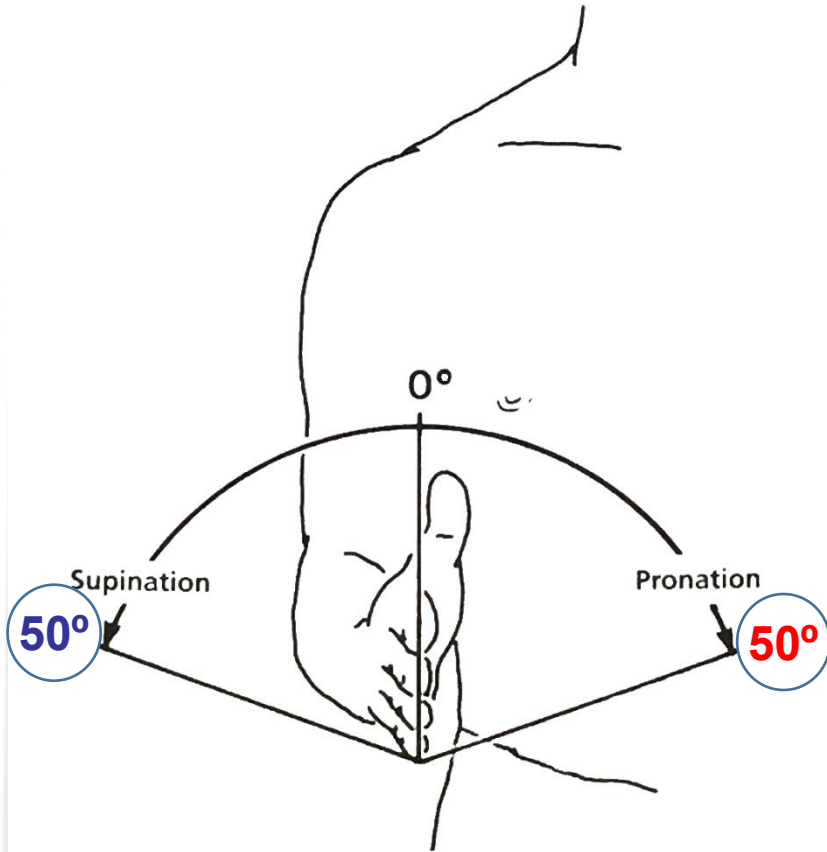
Wrist Radial Deviation = 16° rounds to 20°
 Wrist Ulnar Deviation = 17° rounds to 20°

Wrist Radial Deviation = 20° = 0% UE
 Wrist Ulnar Deviation = 20° = 2% UE



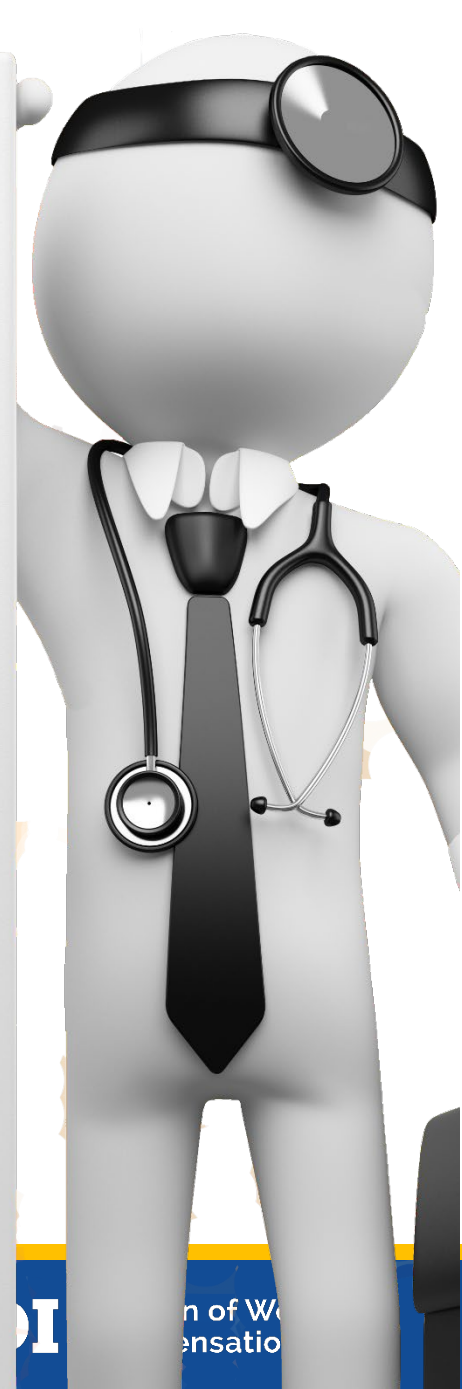Upper Extremity MMI/IR Case 3

Figure 33, Page 40 and Figure 35, Page 41



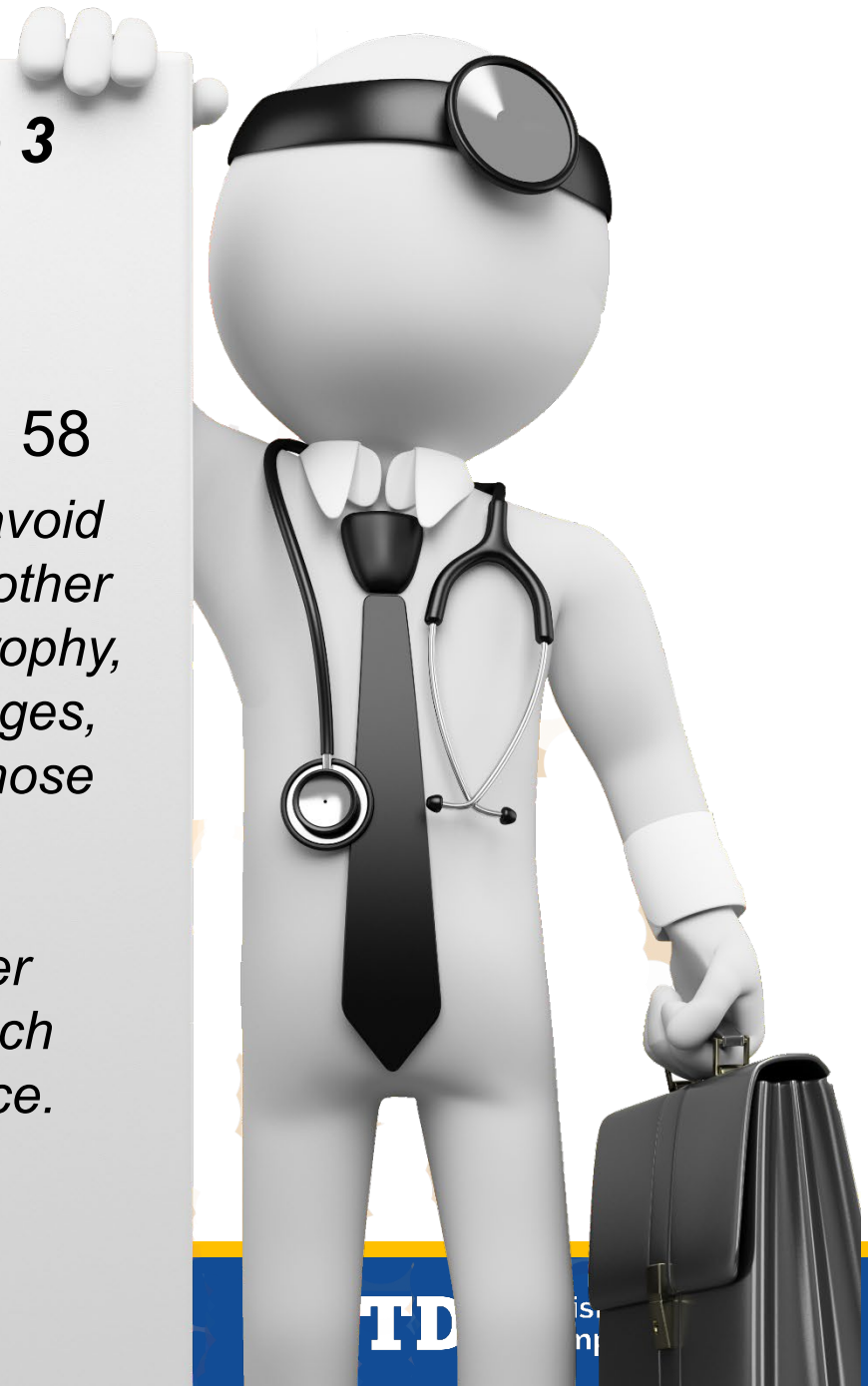
Forearm Pronation = $50^\circ = 2\%$ UE
 Forearm Supination = $50^\circ = 1\%$ UE

Elbow/Forearm ROM = $1\% + 2\% = 3\%$ UE



Upper Extremity MMI/IR Case 3

- What about crepitation?
- See text above Table 18, page 58
 - *The evaluator must take care to avoid duplication of impairments when other findings, such as synovial hypertrophy, carpal collapse with arthritic changes, or limited motion, are present. Those findings might indicate a greater severity of the same pathologic process and take precedence over evaluation of joint crepitation, which should not be rated in that instance.*

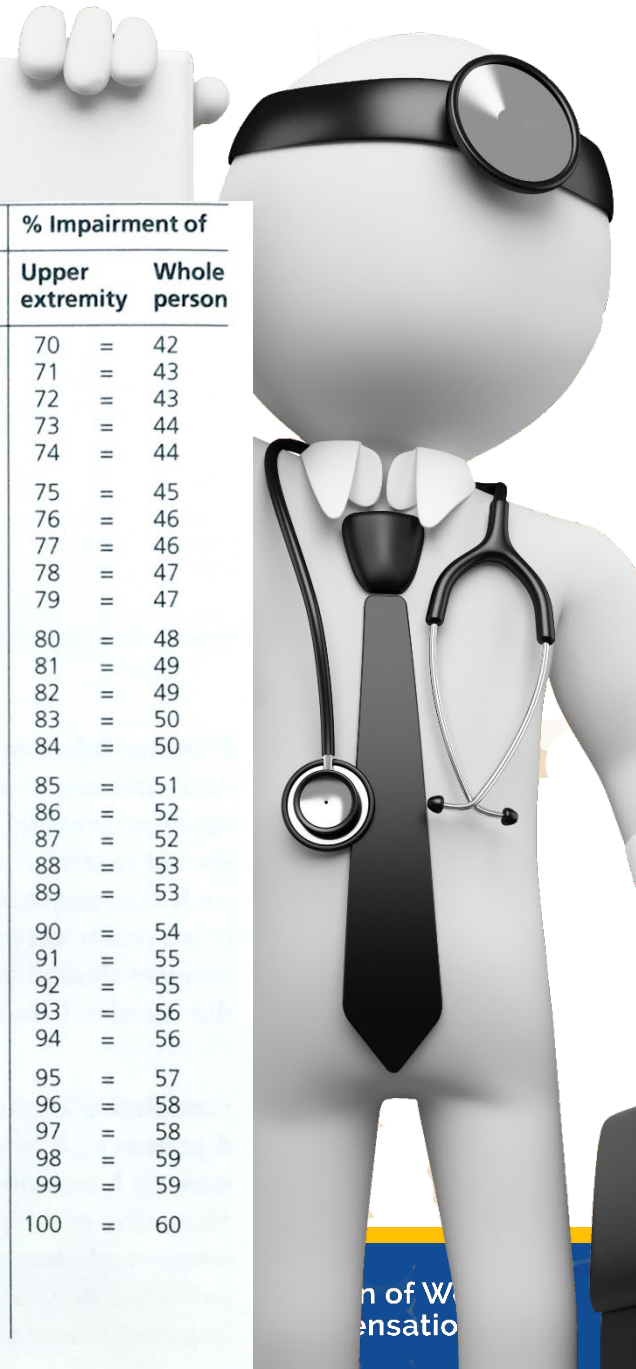


Upper Extremity MMI/IR Case 3

Table 3, Page 20

- Combine ROM
 - Wrist IR% with Elbow/Forearm IR%
- Wrist 11% UE cw
Elbow/Forearm 3% UE
= 14% UE
- Convert: 14% UE = 8% WP

% Impairment of		% Impairment of		% Impairment of				
Upper extremity	Whole person	Upper extremity	Whole person	Upper extremity	Whole person			
0	=	0	35	=	21	70	=	42
1	=	1	36	=	22	71	=	43
2	=	1	37	=	22	72	=	43
3	=	2	38	=	23	73	=	44
4	=	2	39	=	23	74	=	44
5	=	3	40	=	24	75	=	45
6	=	4	41	=	25	76	=	46
7	=	4	42	=	25	77	=	46
8	=	5	43	=	26	78	=	47
9	=	5	44	=	26	79	=	47
10	=	6	45	=	27	80	=	48
11	=	7	46	=	28	81	=	49
12	=	7	47	=	28	82	=	49
13	=	8	48	=	29	83	=	50
14	=	8	49	=	29	84	=	50
15	=	9	50	=	30	85	=	51
16	=	10	51	=	31	86	=	52
17	=	10	52	=	31	87	=	52
18	=	11	53	=	32	88	=	53
19	=	11	54	=	32	89	=	53
20	=	12	55	=	33	90	=	54
21	=	13	56	=	34	91	=	55
22	=	13	57	=	34	92	=	55
23	=	14	58	=	35	93	=	56
24	=	14	59	=	35	94	=	56
25	=	15	60	=	36	95	=	57
26	=	16	61	=	37	96	=	58
27	=	16	62	=	37	97	=	58
28	=	17	63	=	38	98	=	59
29	=	17	64	=	38	99	=	59
30	=	18	65	=	39	100	=	60
31	=	19	66	=	40			
32	=	19	67	=	40			
33	=	20	68	=	41			
34	=	20	69	=	41			



UE MMI/IR Case 3
Figure 1, Part 2 (Page 17)



Questions About Upper Extremity MMI/IR Case 3?



Upper Extremity MMI/IR Case 4

- 58-year-old male auto mechanic injured right shoulder turning large wrench while working overhead on car
- Emergency room records noted painful and limited right shoulder range of motion with positive impingement signs
- X-rays negative with Type III acromion
- Saw orthopedic surgeon and completed 10 visits PT with concurrent subacromial injections with minimal short term benefit and persistent limited ROM and pain

Upper Extremity MMI/IR Case 4

- Right shoulder MRI noted partial thickness tear of supraspinatus tendon, increased signal in subacromial bursa, and type III acromion
- Surgery - arthroscopic rotator cuff tear repair with acromioplasty
- 30 post-operative PT visits with improved ROM and decreased pain

Upper Extremity MMI/IR Case 4

- On Date of MMI Exam Findings Noted
 - Normal 2 point discrimination (PD)
 - Right shoulder ROM
 - flexion 160°
 - extension 40°
 - abduction 120°
 - adduction 30°
 - internal rotation 30°
 - external rotation 30°
 - Constant AC joint crepitation with active right shoulder range of motion
 - Resisted “empty can,” and Neer’s positive for increased right shoulder pain
 - All other upper extremity manual muscle testing 5/5

Upper Extremity MMI/IR Case 4

- On date of MMI, what is whole person IR?
- A. 7%
 - B. 12%
 - C. 11%
 - D. 21%



Upper Extremity MMI/IR Case 4

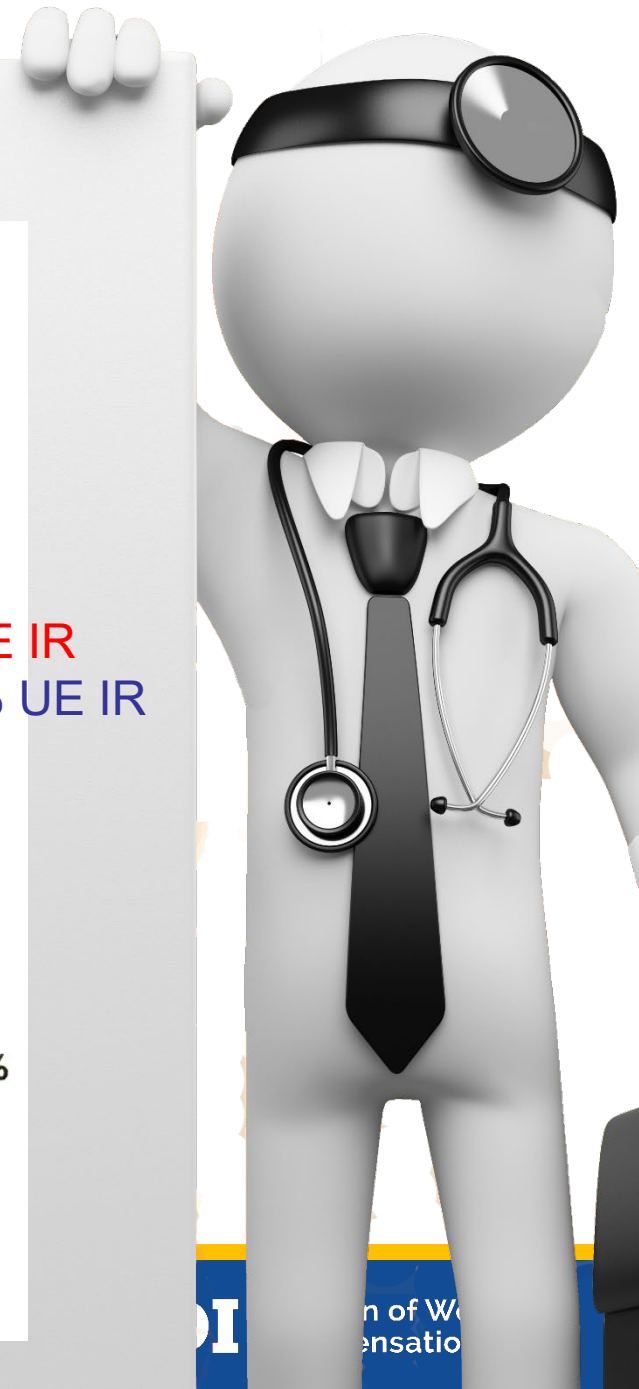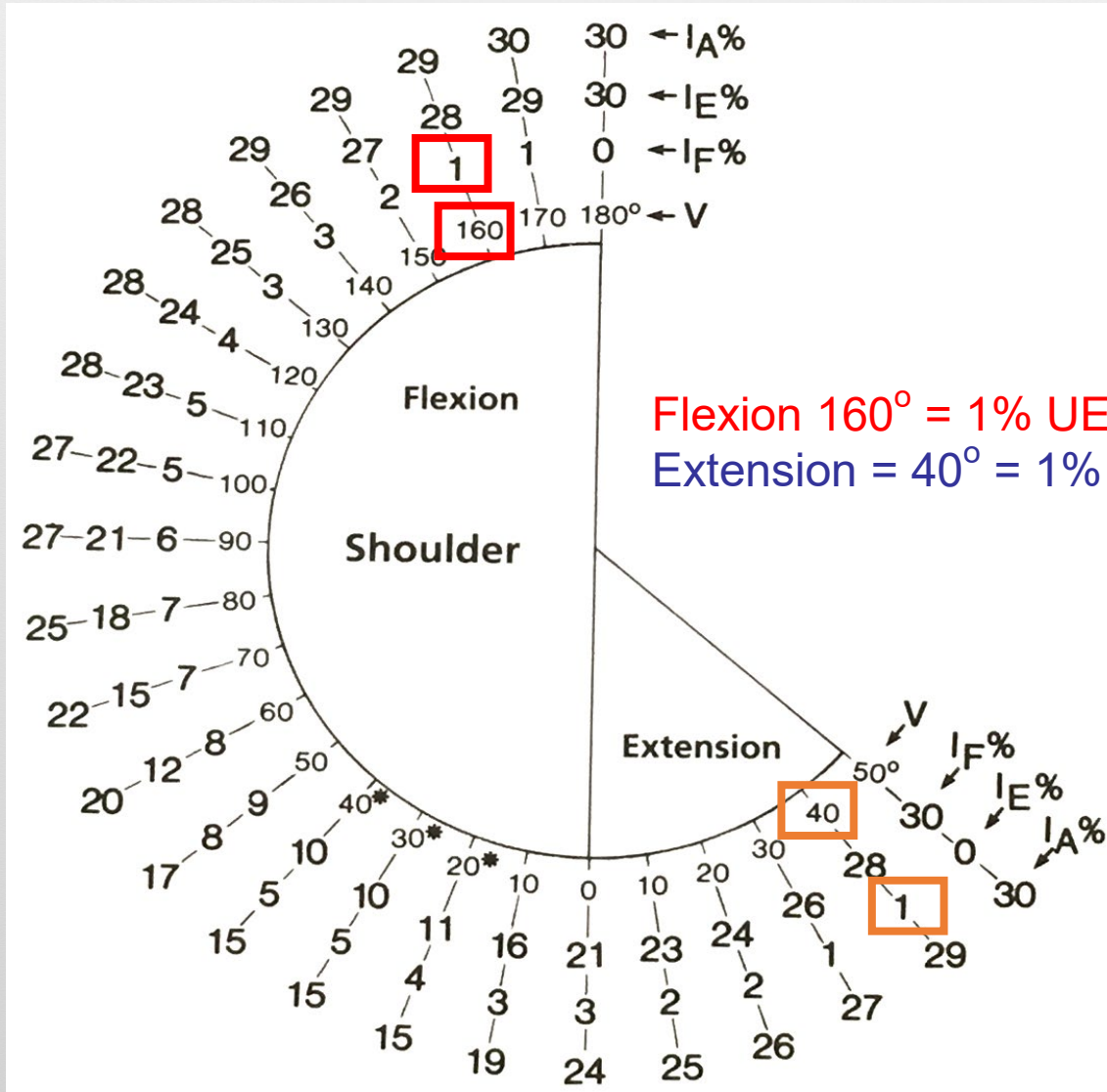
7% WP

- Shoulder ROM
 - flexion 160° = 1% UE
 - extension 40° = 1% UE
 - abduction 120° = 3% UE
 - adduction 30° = 1% UE
 - int. rotation 30° = 4% UE
 - ext. rotation 30° = 1% UE
 - **Total = 11% UE**
- Don't combine crepitation with ROM
 - page 58, above Table 18
- **11% UE = 7% WP**



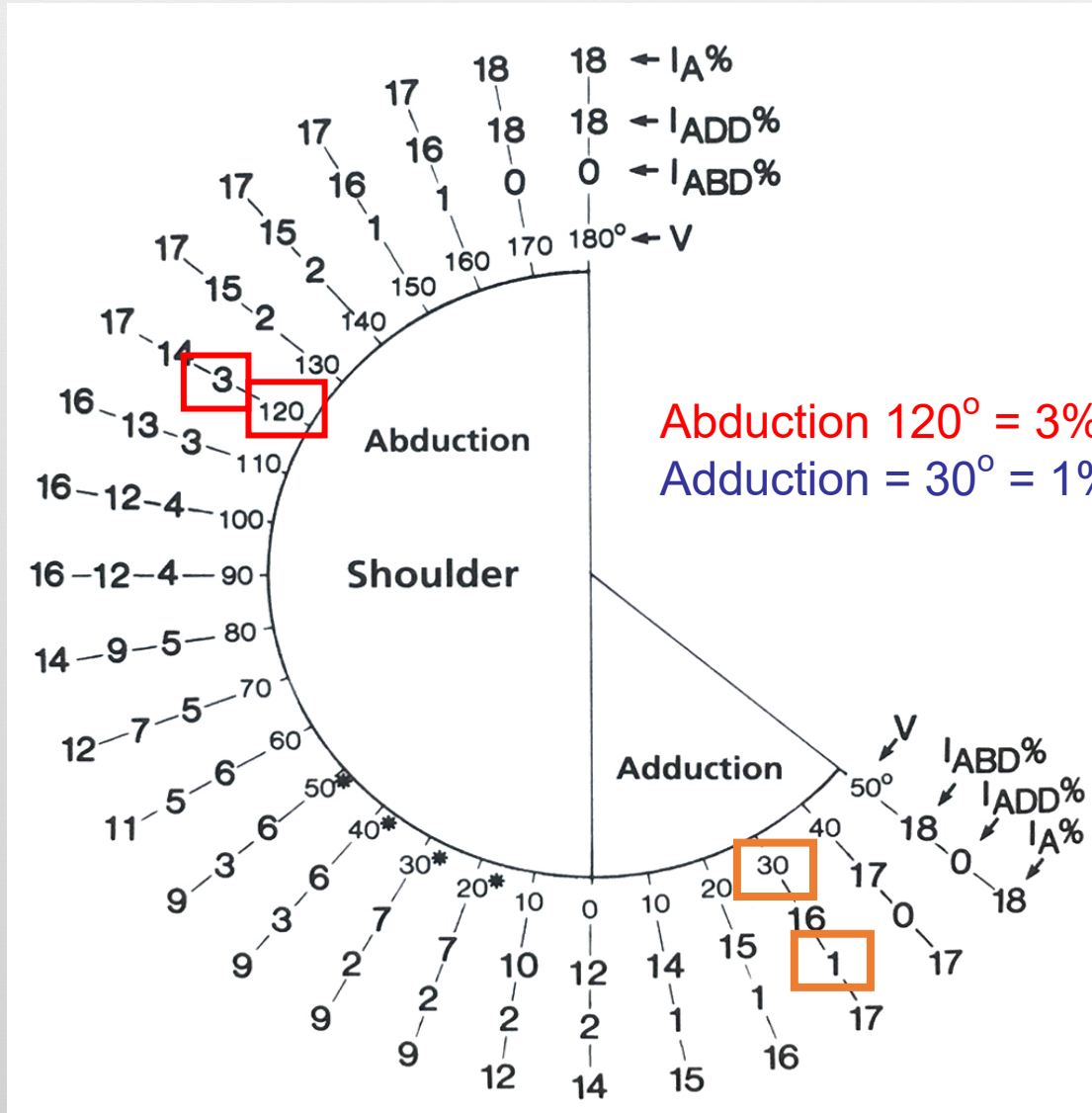
Upper Extremity MMI/IR Case 4

Figure 38, Page 43

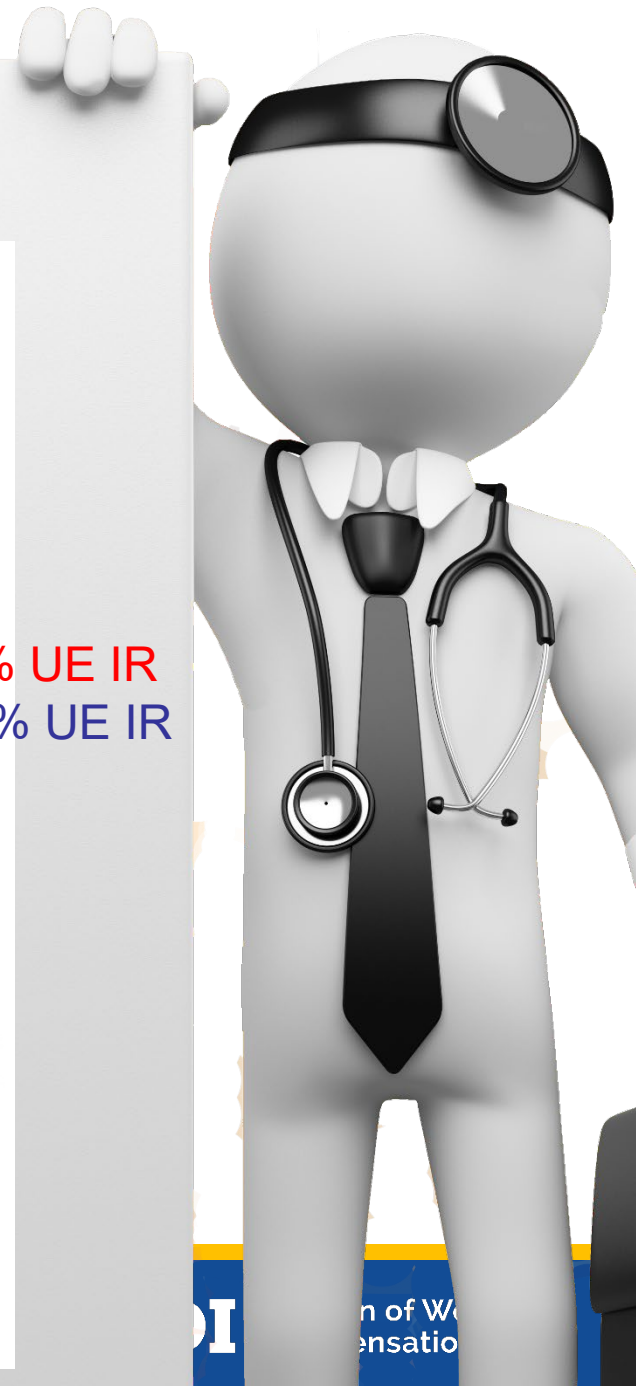

Upper Extremity MMI/IR Case 4

Figure 41, Page 44

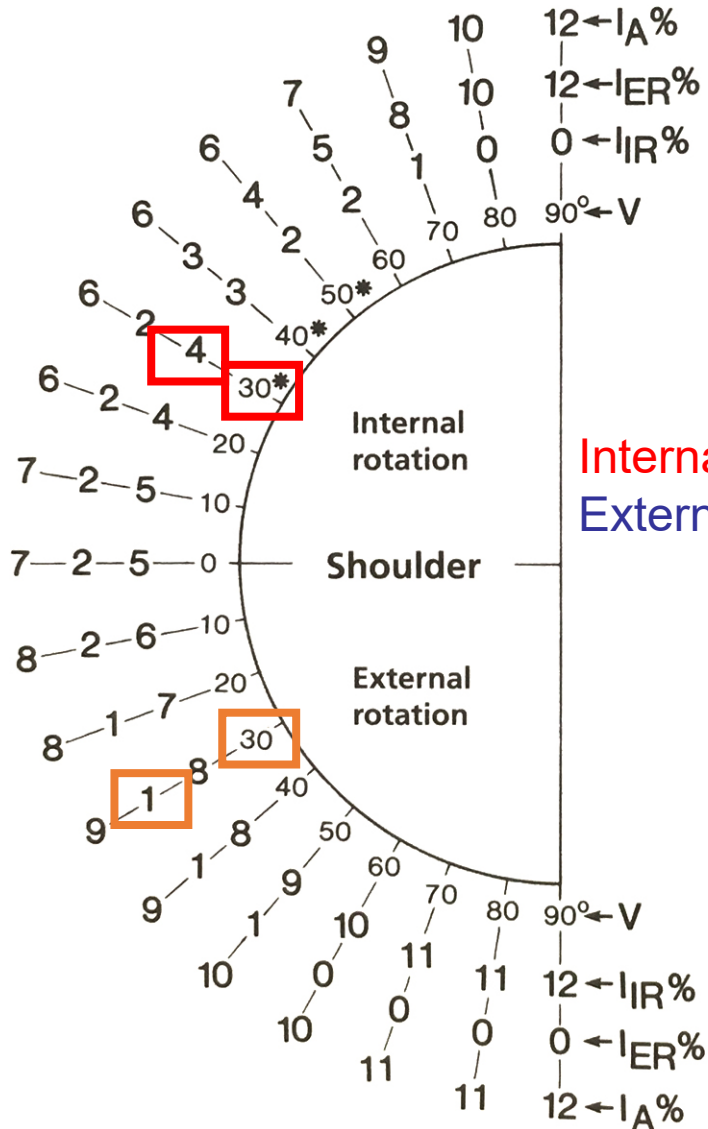


Abduction 120° = 3% UE IR
 Adduction = 30° = 1% UE IR

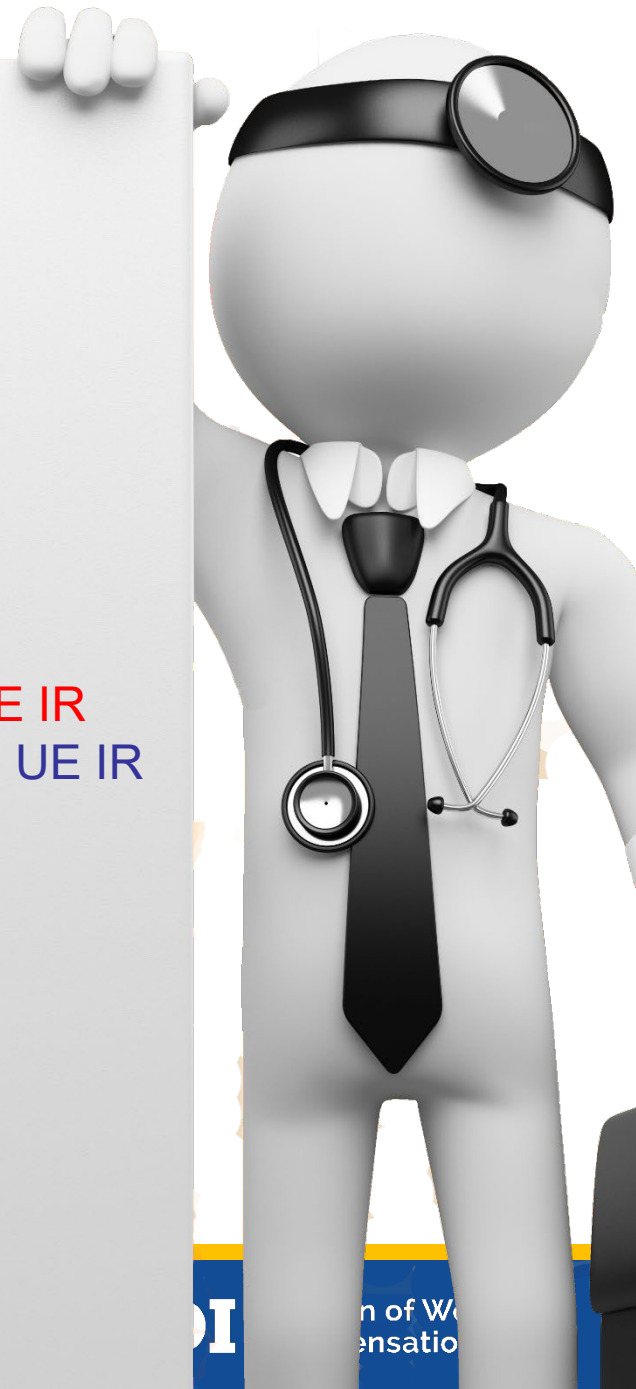

Upper Extremity MMI/IR Case 4

Figure 44, Page 45



Internal Rotation 30° = 4% UE IR
External Rotation = 30° = 1% UE IR



Upper Extremity MMI/IR Case 4

- What if he also had resection arthroplasty of the distal clavicle?



Upper Extremity MMI/IR Case 4

- What if he also had resection arthroplasty of distal clavicle?
- By definition, requires resection of distal clavicular portion of AC joint (not same as acromioplasty)
- Carefully review and cite relevant portions of operative report
- Combine with ROM
 - see Appeals Panel Decision 151158-s

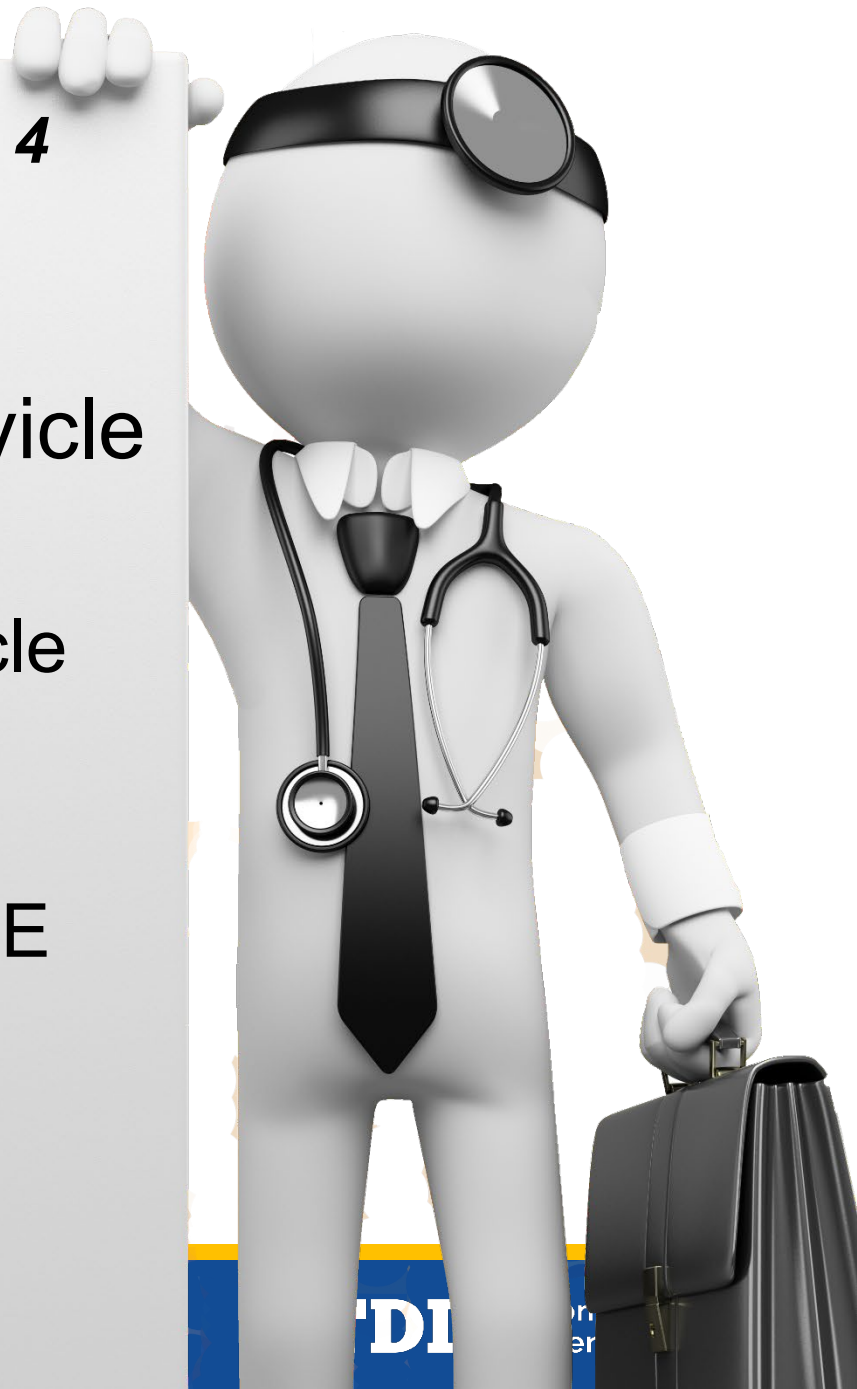Appeals Panel Decision 151158-s

“The language contained on page 3/58 is ambiguous, whereas the language on page 3/62 provides more clear instruction regarding the rating of arthroplasty procedures. Therefore, we hold that impairment for a distal clavicle resection arthroplasty that was received as treatment for the compensable injury results in 10% UE impairment under Table 27, which is then combined with ROM impairment, if any, as provided by the AMA Guides.”

Upper Extremity MMI/IR Case 4

RCR with resection arthroplasty of distal clavicle

- 11% UE for ROM
- 10% UE for distal clavicle resection
 - Table 27, page 61
- 11% cw 10% = 20% UE
- 20% UE converts to
- **12% WP**



Questions About Upper Extremity MMI/IR Case 4?



Questions About Upper Extremity MMI/IR?



Thank you